

# Megacystis Microcolon Intestinal Hypoperistalsis Syndrome (MMIHS): A Case Report in Thailand

Jirapa Manop MD\*,  
Sangkae Chamnanvanakij MD\*, Charnvit Wattanasarn MD\*\*

\* Department of Pediatrics, Phramongkutklao Hospital

\*\* Department of Surgery, Phramongkutklao Hospital

---

*Megacystis microcolon intestinal hypoperistalsis syndrome (MMIHS) is a rare congenital disease with high mortality rate. The authors report a case of a female term infant with massive abdominal distension at birth. Abdominal ultrasonography revealed a huge cystic mass resolved after urinary catheterization. Exploratory laparotomy was performed and intraoperative findings were an enlarged urinary bladder, microcolon, short bowel and malrotation of the small intestine. Ladd's procedure, ileostomy and vesicostomy were performed. Pathological findings of rectal biopsy revealed normal ganglion cells. Although prokinetic drugs were given for promoting bowel motility, enteral feedings were not tolerated. She died from septicemia at the age of 50 days.*

**Keywords :** Megacystis, Microcolon, Hypoperistalsis, MMIHS

**J Med Assoc Thai 2004; 87(11): 1385-8**

**Full text. e-Journal:** <http://www.medassocthai.org/journal>

---

Megacystis-Microcolon-Intestinal Hypoperistalsis Syndrome (MMIHS) is a rare congenital disease characterized by abdominal distension, distended non-obstructive urinary bladder, microcolon, hypoperistalsis and malrotation of the small intestine. The etiology and pathogenesis of this disorder are not clear. Although there is no specific findings for MMIHS, pathological studies of the colon, small intestine and urinary bladder are important for differentiating from other diseases. There is no specific treatment and prognosis is very poor. The authors reported the first case of a Thai infant who had typical manifestation of MMIHS with pathological studies of the intestine.

## Case Report

A female 2,300-gram infant was born by cesarean section at 31 weeks of gestation. Prenatal history was unremarkable except for polyhydramnios. There was no family history of congenital anomalies.

---

*Correspondence to : Chamnanvanakij S, Division of Neonatology, Department of Pediatrics, Phramongkutklao Hospital, 315 Rajavithree Rd, Bangkok 10400, Thailand. Phone: 0-2354-7660 ext. 94109, 94180, Fax: 0-2248-4191, E-mail: sangkae@hotmail.com*

Physical examination at birth revealed markedly distended abdomen with a large movable, ill-defined mass at the middle part of the lower abdomen. The abdominal wall looked normal. Hypoactive bowel sound was noted.

Blood urea nitrogen (BUN) and serum creatinine on the first day of life were 23.24 mg/dL and 1.8 mg/dL, respectively. She had metabolic acidosis with serum bicarbonate of 16.3 mmol/L. Urinalysis on the same day showed pH of 8.0, and specific gravity of 1.005 without protein, sugar, white blood cell or red blood cell. The infant also had low serum calcium level of 5.96 mg/dL and was treated with 10% calcium gluconate. The levels of BUN and serum creatinine declined gradually to 8 mg/dl and 0.7 mg/dL, respectively within the first week. Although sodium bicarbonate was given, she continued to have metabolic acidosis until 2 weeks of age. Ultrasonography of the abdomen showed a large cystic mass with bilateral hydronephrosis and hydroureter (Fig. 1). Normal liver, gall bladder, spleen and biliary system were noted. There was no ascites.

Computerized tomography of abdomen showed a huge cystic mass sized 10x17x7 cm. The mass had a pressure effect on proximal part of the duodenum causing a markedly dilated stomach.

Voiding cystoureterography showed markedly distended urinary bladder (Fig. 2). The wall of the bladder was smooth without intrinsic or extrinsic lesion. No demonstration of vesicoureteral reflux was noted. The urethra was not evaluated because of no voiding phase.

Upper gastrointestinal study showed a distended stomach with normal gastric contour and duodenal cap (Fig. 3). There was marked delay of gastric emptying time because of narrowing of the second part of duodenum.

Since the first day of life, she was given nothing per oral and parenteral nutrition was started. Abdominal distension decreased dramatically after placing a urine catheter to release 120 milliliters of urine. Urine catheter was retained and urine output was 3-4 ml/kilogram/day. On the 16<sup>th</sup> day of age, explore laparotomy was performed. The operation revealed micro-colon, malrotation of small intestine, small terminal ileum, short bowel and a huge urinary bladder. Surgical procedures including Ladd's procedure, ileostomy and cutaneous vesicostomy were performed. Pathologic findings of bowel biopsy showed no significant pathological changes of ileal, appendix, sigmoid and colon. Rectal biopsy revealed normal ganglion cells.

A week after the operation, she received a very small amount of enteral nutrients by continuous gastric infusion. Prokinetic drugs, erythromycin and cisapride, were given for promoting bowel motility. She couldn't tolerate enteral feedings and continued to receive total parenteral nutrition.

During the hospital course, she had many episodes of urinary tract infection (UTI). The first episode was at the age of 5 days with *Enterobacter cloacae*. She was initially treated with cefotaxime and amikacin but changed to ceftazidime and then to imipenem. The infection resolved after a 14-day course of antibiotics. At 27 days of age, she developed the second episode of UTI. Budding yeasts were noted in urine and urine culture was positive for *Candida albicans*. She was treated with Amphotericin B. At 38 days of age, she developed UTI and clinical sepsis. Meropenem was started and cystostomy tube was removed. However, she died 12 days later. Blood and urine cultures before starting antibiotics grew *Enterobacter cloacae*.

#### Discussion:

Since Berdon et al reported 5 cases of MMIHS in 1976<sup>(1)</sup>, there were only a hundred cases reported in the medical literature. MMIHS is a rare congenital

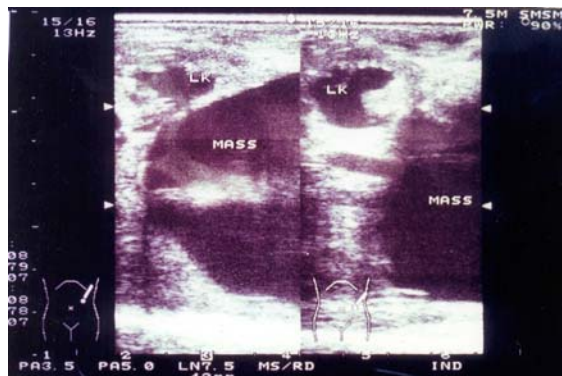


Fig. 1 Ultrasonography of abdomen: large cystic mass with hydronephrosis

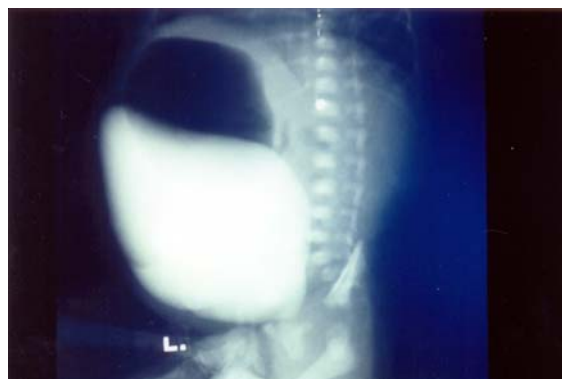

Fig. 2 Voiding cystoureterography: markedly distended urinary bladder

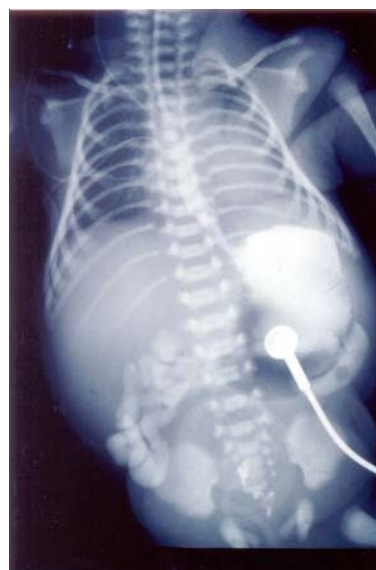

Fig. 3 Upper gastrointestinal study: distended stomach with normal gastric contour and duodenal cap

disease found more commonly in female infants. Although a few cases have been reported in siblings as autosomal recessive inheritance<sup>(2,3)</sup>, most cases occur sporadically. The etiology and pathogenesis of the disease are not clear. However, many hypothesis have been proposed such as degenerative disease of smooth muscle<sup>(4)</sup>, disturbance in bowel innervation<sup>(5,6)</sup>, imbalance of gut peptides<sup>(7)</sup>, in utero intramural inflammatory process of gastrointestinal and urinary tract<sup>(8)</sup>, defect of contractile fiber synthesis<sup>(9)</sup>, and drugs<sup>(10-12)</sup>.

The common manifestations of this disease include megacystis, hydronephrosis or hydroureter, abdominal distension, microcolon, and intestinal hypoperistalsis reported in more than 80% of patients<sup>(1,3,4,6-9,13-22)</sup>. Some patients have other associated anomalies such as megaesophagus<sup>(22)</sup>, hydrometrocolpos<sup>(21)</sup>, and Barrett's esophagus<sup>(20)</sup>.

Some manifestations of MMIHS can be identified prenatally by routine prenatal ultrasonography such as distended stomach and urinary bladder, increased amniotic fluid, dilated renal calyces and megareter<sup>(19)</sup>. The most important ultrasonographic finding is distended urinary bladder without oligohydramnios which is different from obstructive uropathy diseases. The earliest time to detect distended urinary bladder and hydronephrosis was at 16-20 weeks<sup>(19)</sup>.

Diagnosis of MMIHS is based on the presence of clinical characteristics including, megacystis, microcolon, intestinal malrotation, short bowel and intestinal hypoperistalsis in the absence of anatomical obstruction. The differential diagnosis depends on the main manifestations. For megacystis, differentiations from other anomalies of genitourinary tract such as prune belly syndrome, urethral agenesis and variant of caudal regression are needed. For microcolon, the differential diagnosis includes intestinal atresia, volvulus and total colon aganglionosis. Other secondary causes of ileus or pseudoobstruction such as hypothyroidism, hypokalemia and narcotics must be excluded.

Manometric studies shows that the frequency and amplitude of spontaneous contraction in the stomach and small intestine are significantly lower or absent compared to healthy controls<sup>(4,23)</sup>.

Pathological findings of gastrointestinal tract are varied. Abnormal findings reported include vacuolar degeneration of smooth muscle cells<sup>(4,8)</sup> and shrunken neuron<sup>(6)</sup>. However, the most important finding of MMIHS is normal or increased ganglion cells<sup>(3,4,6-9,13,14,18-22)</sup> which is different from total aganglionosis.

Nutritional support is the mainstay of treatment. Hyperalimentation is required. Palliative surgery such as jejunostomy or cystostomy is generally needed. Prokinetic drugs for promoting bowel motility are ineffective<sup>(3,4,9,23)</sup>. Totally digested enteral nutrients by continuous infusion through jejunostomy was reported in one case to improve the problem of feeding intolerance<sup>(17)</sup>. A cholinergic drug, bethanechol, was partially effective to improve peristalsis in one patient<sup>(16)</sup>. Only one report showed the success of multivisceral transplantation in MMIHS patients<sup>(24)</sup>. MMIHS is lethal disease. Most patients died within one year after birth from severe infection. Only a few cases have been reported to survive until 4-11 years of age<sup>(8,9,17)</sup>.

Even though most cases occur sporadically, the recurrence risk in subsequent pregnancies is up to 25% because there are reports of MMIHS in siblings<sup>(2,3)</sup>. Therefore, prenatal ultrasonography is recommended to identify a case in subsequent pregnancies.

## Reference

1. Berdon WE, Baker DH, Blanc WA, Gay B, Santulli TV, Donovan C. Megacystis-microcolon-intestinal hypoperistalsis syndrome: a new cause of intestinal obstruction in the newborn. Report of radiologic findings in five newborn girls. *Am J Roentgenol* 1976; 126: 957-64.
2. Garber A, Shohat M, Sarti D. Megacystis-microcolon-intestinal hypoperistalsis syndrome in two male siblings. *Prenat Diagn* 1990; 10: 377-87.
3. Anneren G, Meurling S, Olsen L. Megacystis-microcolon-intestinal hypoperistalsis syndrome (MMIHS), an autosomal recessive disorder: clinical reports and review of the literature. *Am J Med Genet* 1991; 41: 251-4.
4. Puri P, Lake BD, Gorman F, O'Donnell B, Nixon HH. Megacystis-microcolon-intestinal hypoperistalsis syndrome: a visceral myopathy. *J Pediatr Surg* 1983; 18: 64-9.
5. Kubota M, Ikeda K, Ito Y. Autonomic innervation of the intestine from a baby with megacystis microcolon intestinal hypoperistalsis syndrome: II. Electrophysiological study. *J Pediatr Surg* 1989; 24: 1267-70.
6. Kirtane J, Talwalker V, Dastur DK. Megacystis, microcolon, intestinal hypoperistalsis syndrome: possible pathogenesis. *J Pediatr Surg* 1984; 19: 206-8.
7. Taguchi T, Ikeda K, Shono T, Goto S, Kubota M, Kawana T, Hirose R, Toyohara T. Autonomic innervation of the intestine from a baby with megacystis microcolon intestinal hypoperistalsis syndrome: I. Immunohistochemical study. *J Pediatr Surg* 1989; 24: 1264-6.
8. Srikanth MS, Ford EG, Isaacs H Jr, Mahour GH. Megacystis microcolon intestinal hypoperistalsis

- syndrome: late sequelae and possible pathogenesis. *J Pediatr Surg* 1993; 28: 957-9.
9. Ciftci AO, Cook RC, van Velzen D. Megacystis microcolon intestinal hypoperistalsis syndrome: evidence of a primary myocellular defect of contractile fiber synthesis. *J Pediatr Surg* 1996; 31: 1706-11.
  10. Balkan E, Noyan S, Sirmali S, Dogruyol H. Does maternal drug ingestion cause megacystis microcolon intestinal hypoperistalsis syndrome? I. Clomiphene trial. *Clin Exp Obstet Gynecol* 1999; 26: 100-4.
  11. Balkan E, Noyan S, Sirmali S, Dogruyol H. Does maternal drug ingestion cause megacystis microcolon intestinal hypoperistalsis syndrome? II. Bromide trial. *Clin Exp Obstet Gynecol* 1999; 26: 232-6.
  12. Balkan E, Noyan S, Sirmali S, Dogruyol H. Does maternal drug ingestion cause megacystis microcolon intestinal hypoperistalsis syndrome? III. Ethanol trial. *Clin Exp Obstet Gynecol* 1999; 26: 237-41.
  13. Amoury RA, Fellows RA, Goodwin CD, Hall RT, Holder TM, Ashcraft KW. Megacystis-microcolon-intestinal hypoperistalsis syndrome: A cause of intestinal obstruction in the newborn period. *J Pediatr Surg* 1977; 12: 1063-5.
  14. Patel R, Carty H. Megacystis-microcolon-intestinal hypoperistalsis syndrome: a rare cause of intestinal obstruction in the newborn. *Br J Radiol* 1980; 53: 249-52.
  15. Wiswell TE, Rawlings JS, Wilson JL, Pettett G. Megacystis-microcolon-intestinal hypoperistalsis syndrome. *Pediatrics* 1979; 63: 805-8.
  16. Jona JZ, Werlin SL. The megacystis microcolon intestinal hypoperistalsis syndrome: report of a case. *J Pediatr Surg* 1981; 16: 749-51.
  17. Gillis DA, Grantmyre EB. Megacystis-microcolon-intestinal hypoperistalsis syndrome: survival of a male infant. *J Pediatr Surg* 1985; 20: 279-81.
  18. al-Rayess M, Ambler MW. Axonal dystrophy presenting as the megacystis-microcolon-intestinal hypoperistalsis syndrome. *Pediatr Pathol* 1992; 12: 743-50.
  19. Carlsson SA, Hokegard KH, Mattsson LA. Megacystis-microcolon-intestinal hypoperistalsis syndrome. Antenatal appearance in two cases. *Acta Obstet Gynecol Scand* 1992; 71: 645-8.
  20. Kupferman JC, Stewart CL, Schapfel DM, Kaskel FJ, Fine RN. Megacystis-microcolon-intestinal hypoperistalsis syndrome. *Pediatr Nephrol* 1995; 9: 626-7.
  21. Dewan PA, Brown N, Murthy DP, Danga-Christian B, Haan E, Byard RW, Watters DA. Hydrometrocolpos and segmental colonic dilatation in a girl with megacystis-microcolon-intestinal hypoperistalsis syndrome. *J Pediatr Child Health* 1995; 31: 479-82.
  22. Al Harbi A, Tawil K, Crankson SJ. Megacystis-microcolon-intestinal hypoperistalsis syndrome associated with megaesophagus. *Pediatr Surg Int* 1999; 15: 272-4.
  23. Shono T, Suita S, Taguchi T, Nagasaki A. Manometric evaluation of gastrointestinal motility in a case of megacystis-microcolon-intestinal hypoperistalsis syndrome (MMIHS). *Eur J Pediatr Surg* 1992; 2: 52-5.
  24. Masetti M, Rodriguez MM, Thompson JF, Pinna AD, Kato T, Romaguera RL, Nery JR, DeFaria W, Khan MF, Verzaro R, Ruiz P, Tzakis AG. Multivisceral transplantation for megacystis microcolon intestinal hypoperistalsis syndrome. *Transplantation* 1999; 68: 228-32.

---

## Megacystis Microcolon Intestinal hypoperistalsis syndrome (MMIHS): รายงานผู้ป่วยในประเทศไทย

จิราภา มานพ, แสงแข ขำนาญวณิช, ชาญวิทย์ วัฒนสานต์

Megacystis Microcolon Intestinal Hypoperistalsis Syndrome (MMIHS) เป็นกลุ่มอาการผิดปกติแต่กำเนิดที่มีลักษณะกระเพาะปัสสาวะขนาดใหญ่โดยไม่มีการอุดตันที่ส่วนปลาย ลำไส้ใหญ่ขนาดเล็ก และมีการเคลื่อนไหวของลำไส้ช้ากว่าปกติ เป็นกลุ่มอาการที่พบได้น้อย ยังไม่ทราบพยาธิกำเนิดที่ชัดเจน และมีการพยากรณ์โรคไม่แน่นอน บทความนี้รายงานผู้ป่วยเพศหญิง 1 ราย ที่มีท้องโตผิดปกติตั้งแต่แรกเกิด ตรวจเพิ่มเติมพบว่า มีกระเพาะปัสสาวะขนาดใหญ่ ร่วมกับมีท่อไตและกรวยไตขยายใหญ่ ลำไส้เล็กส่วนปลายและลำไส้ใหญ่มีขนาดเล็ก และมีการหมุนตัวของลำไส้ผิดปกติ ผลการตรวจทางพยาธิวิทยาของลำไส้ไม่พบความผิดปกติ ได้รับการผ่าตัดด้วยวิธี Ladd's procedure, ileostomy และ cutaneous vesicostomy ได้รับสารอาหารทดแทนทางหลอดเลือดดำ และยากระตุ้นการเคลื่อนไหวของลำไส้ แต่ผู้ป่วยไม่สามารถรับประทานอาหารทางปากได้ และไม่สามารถปัสสาวะได้เอง ผู้ป่วยเสียชีวิตเมื่ออายุ 50 วัน เนื่องจากการติดเชื้อในกระแสเลือด