

***Nocardia* Pneumonia with Empyema Thoracis in a Healthy Neonate: A Case Report**

Taweewong Tantracheewathorn MD*,
Somsak Lolekha MD, PhD**, Supapan Tantracheewathorn MD*

*Presented at the 1st Asian Congress of Pediatric Infectious Diseases,
Pattaya, Thailand, November 10-13, 2002*

* *Department of Pediatrics, Bangkok Metropolitan Administration Medical College and Vajira Hospital*

** *Department of Pediatrics, Faculty of Medicine, Ramathibodi Hospital, Mahidol University*

A 40-day-old male infant presented with fever and non-productive cough for 3 weeks, tachypnea and dyspnea 5 days before admission. The chest radiograph and computed tomographic (CT) scan revealed right lung consolidation with pleural effusion. Pleural tapping showed frank pus that grew *Nocardia asteroides*. The CT scan of the brain and abdomen were normal. The patient was treated with 15 mg/kg/day of trimethoprim and 75 mg/kg/day of sulfamethoxazole intravenously for 3 weeks and then orally for 6 months with complete recovery. T cell quantitative studies were normal and anti-HIV was non-reactive. A flow cytometric assay with *Staphylococcus aureus* and phorbol myristate acetate (PMA) as the stimulants showed normal oxidative burst which represented normal intracellular killing. One year after completion of treatment, he was healthy and the chest radiograph was normal.

Keywords : *Nocardia, Nocardiosis, Pneumonia, Empyema Thoracis*

J Med Assoc Thai 2004; 87(4): 438-41

Nocardiosis is caused by ubiquitous aerobic actinomycetes that exist throughout the world as soil and dust saprophytes. The disease mainly occurs as a secondary infection in patients with chronic granulomatous disease (CGD) and an impaired cell-mediated immune response (CMIR) such as HIV disease, neoplastic disease, recipients of organ transplants, those receiving corticosteroids and chemotherapeutic agents^(1,2). Nocardiosis is an uncommon infection which occurs infrequently in children. This is the first reported case of pneumonia with empyema thoracis caused by *Nocardia asteroides* in a healthy neonate in Thailand and there are few cases of nocardial infections in neonates in the world literature⁽³⁻⁵⁾.

Case Report

A 40-day-old male infant was referred to us with progressive dyspnea for 5 days. Three weeks before admission he had fever and nonproductive

cough and was treated at a private clinic with no improvement. Two weeks later he was admitted to a government hospital because of pneumonia and empyema thoracis of the right lung. He was treated with cefotaxime (100 mg/kg/day), amikacin (15 mg/kg/day) intravenously with intercostal chest drainage but still had progressive dyspnea. He was intubated and referred to Vajira Hospital. He was a term, 3,000 g newborn and delivered by normal labour with no antenatal, natal and postnatal complications. He lived with his family in Bangkok and had no history of contact with infectious diseases or exposure to pets.

Physical examination disclosed a body temperature of 37.4 °C, pulse rate of 140 /minute, respiratory rate of 56 /minute and blood pressure of 60/37 mmHg. Decreased breath sound and dullness on percussion were noted at the right lung. He had 2 intercostal drainage (ICD) lines on the 2nd and 5th intercostal spaces of the right chest which released yellowish pus. The remaining physical examination was normal.

The laboratory investigations revealed a hemoglobin of 9.1 g/dl, hematocrit of 29.4 per cent,

Correspondence to : Tantracheewathorn T, 582/3 Soi Charun Sanitwong 13 Rd, Bangplad, Bangkok 10700, Thailand.
Phone: 0-2243-6251, Fax: 0-2243-6251, E-mail: taweewong3@hotmail.com

white blood cell count of 46,100 cells/mm³ with 84 per cent neutrophils, 9 per cent lymphocytes, 2 per cent eosinophils, 5 per cent monocytes and normal platelet count. Cerebrospinal fluid cytology was normal. The chest radiograph showed non-homogenous opacity and consolidation at the right lung (Fig. 1). A computed tomographic (CT) scan revealed soft tissue density replacement of lung parenchyma with internal air bronchogram and cystic lesions at the right middle and upper lungs (Fig. 2). Gram stain of pus from the ICD line demonstrated numerous gram-positive branching filaments which were acid fast by modified AFB staining. The patient was initially treated with intravenous cefotaxime (150 mg/kg/day), amikacin (20 mg/kg/day) and trimethoprim-sulfamethoxazole (15 mg/kg/day of trimethoprim). Clinical improvement was noted with resolution of fever and reduction of pus from the ICD line. Six days later the pus culture on Sabouraud dextrose agar grew *Nocardia asteroides* which was susceptible to trimethoprim-sulfamethoxazole (TMP-SMX), kanamycin, gentamicin, amikacin, netilmicin, tetracycline, levofloxacin and meropenem. The susceptibility testing was performed on Mueller-Hinton agar by modified disk diffusion, as recommended by the NCCLS. Cefotaxime and amikacin were discontinued. Intravenous TMP-SMX were continued for 3 weeks, followed by 6 months of oral form. Periodic chest radiographs showed progressive clearing of the right lung. The CT chest at 2 months of treatment revealed mild residual consolidation of the right middle lung, no mass and effusion. The CT brain and abdomen were normal representing no metastasis. The child was followed up for 1 year after completion of treatment, he was clinically well with no recurrence of disease and had a normal chest radiograph (Fig. 3).

On the basis of finding *Nocardia* on the culture of the lung aspirate, immunologic investigations were undertaken. T cell quantitative studies were normal (total lymphocytes 3,340 cells/mm³ (63%), CD4 count of 2,540 cells/mm³ (48%), CD8 count of 800 cells/mm³ (15%), CD4/CD8 3.2) and anti-HIV was non-reactive. Tuberculin test produced a 10 mm wheal. A flow cytometric assay with *Staphylococcal aureus* and phorbol myristate acetate (PMA) as the stimulants showed normal phagocytosis and oxidative burst.

Discussion

Nocardiosis is an acute, subacute or chronic suppurative infection caused by *Nocardia* species. Localized cutaneous or lymphocutaneous infection

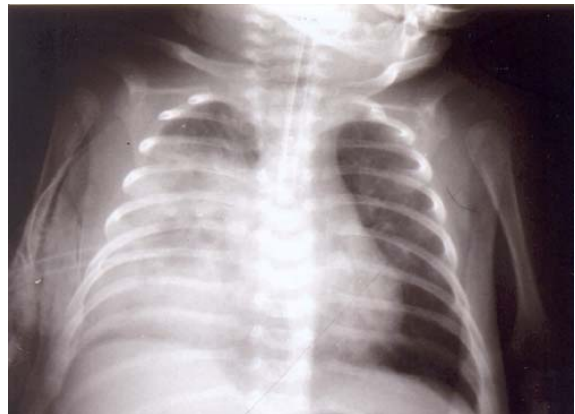


Fig. 1 Chest radiograph on admission reveals large non-homogenous opacity and consolidation with ICD line of the right lung

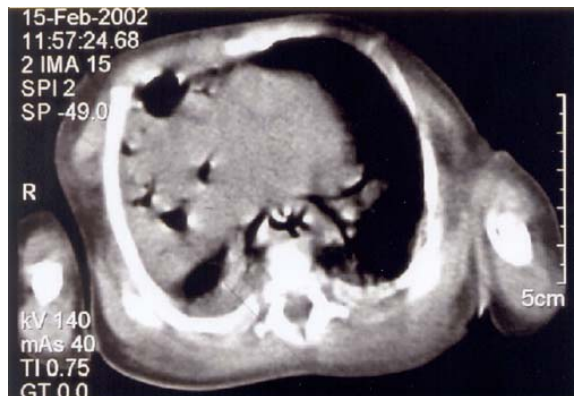


Fig. 2 CT of the chest on the second day of admission demonstrating a solid mass with cystic areas of the right lung

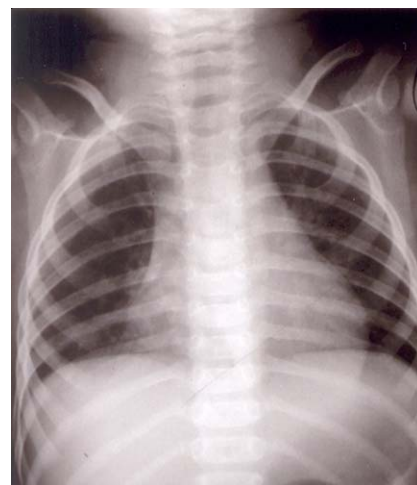

Fig. 3 Chest radiograph at 1 year after completion of treatment showing completion resolution of infiltrates

usually occurs in immunocompetent hosts after soil contamination through injured skin. Invasive and pulmonary infections mainly occur in an immunocompromised host. Pulmonary infection via inhalation of contaminated airborne dust particles may be subclinical or transient or may provoke an acute or chronic process mimicking staphylococcal or fungal pneumonia, tuberculosis or carcinoma. Hematogenous dissemination may occur from the lungs to the brain, kidney, liver and all organs of the body^(1,2). Suppression of cellular immunity and chronic granulomatous disease (CGD) are important risk factors for *Nocardia* infections. Immune T cells are vital in clearing *Nocardia* species from the lungs and preventing dissemination. Neutrophils only inhibit the organisms and limit the spread of infection until an adequate cell-mediated immune response (CMIR) develops or effective antimicrobial agents are given^(2,6). This patient had no risk factors for *Nocardia* infection. He had an uneventful antenatal, natal and postnatal history. He was healthy until onset of the illness. His assays of neutrophils function and CMIR were normal. Although the neonate had immature immune function, there are few reports of invasive nocardial infection in this age group. The authors searched the reference available on MEDLINE and Thai Index Medicus but found no previous case report from Thailand and there are only a few cases in the world literature (Table 1).

Nocardia species are ubiquitous environmental saprophytes, living in soil, organic matter and water. Animal-to-human or human-to-human or vertical transmission has not been reported^(1,7,8). They are extremely rare as lung pathogens in neonates but easily diagnosed by modified AFB stain, culture and susceptibility testing. They will grow on most nonselective media used routinely for culture of bacteria, fungi and mycobacteria⁽²⁾. This patient had an onset of fever and respiratory symptoms at 20-days old. He was presumed to be infected via inhalation. The

pathogen grew on Sabouraud dextrose agar which is a commonly used fungal media.

The chest radiographs of pulmonary nocardiosis may demonstrate fluffy infiltrates, irregular densities, pleural empyema, single or scattered regular or irregular nodules or masses which often cavitate, single or multiple abscesses and even interstitial, reticulonodular, alveolar or rarely miliary infiltrates^(4,7,9). Johnston et al⁽³⁾ reported *Nocardia* pneumonia in a neonate with CGD. The chest CT scan revealed a solid mass with a few cystic areas, interpreted as a cystic adenomatoid malformation. A large necrotic mass was resected. Culture from the resected mass grew *N. asteroides* and TMP-SMX were given with good response. The presented patient highlights the importance that pulmonary nocardiosis can present with a large cystic mass and has good response with TMP-SMX without resection.

Although optimal antimicrobial regimens have not been established by controlled clinical trials, sulfonamides have been the mainstay of therapy since the 1940s. Co-trimoxazole is currently preferred in a dose of 15 mg/kg/day of TMP and 75 mg/kg/day of SMX, either parenterally or orally^(2,6,7). In invasive cases, a combination of amikacin and imipenem with cefotaxime and TMP-SMX display synergy for most *Nocardia* strains, although the value of combined therapy remain unsettled. Because of the tendency of relapse or late metastatic disease, treatment must be continued for many months⁽²⁾. Immunocompetent patients with pulmonary or systemic nocardiosis should be treated for at least 6 months, and those with CNS involvement for 12 months⁽⁶⁾.

Acknowledgements

The authors wish to thank Dr. Rojanakorn Singkalavanij, the Head of the Department of Pediatrics, BMA Medical College and Vajira Hospital for permission to report this data, Dr. Preeda Sangacharoenkit

Table 1. Reported nocardial infection in neonates

Case	Author Country-Year	Age Sex	Organs involved	<i>Nocardia</i> species	Underlying diseases	Treatment	Outcome
1	Jonston ⁽³⁾ USA-1989	1 month M	Lung	<i>N. asteroides</i>	CGD	Resection TMP-SMX	Survived
2	Kim ⁽⁴⁾ Korea-1992	18 day F	Lung, Kidney, Brain	Species not specified	No investigation	Antituberculous drugs	Died
3	Singh ⁽⁵⁾ India-2003	2 months M	Lymph node, Dissemination	<i>N. farcinica</i>	No investigation about CGD,CMIR	Amikacin TMP-SMX	Survived

and Mrs. Huttaya Thuncharoon from Taksin Hospital for referring the case and for some laboratory results.

References

1. Johann-Liang R. Nocardiosis. eMedicine [Online] 2003 Luly [cited 2003 September 5]. Available from: URL: <http://www.emedicine.com/ped/topic1610.htm>.
2. Darville T, Jacobs RF. *Nocardia*. In: Feigin RD, Cherry JD, eds. Textbook of pediatric infectious diseases. 4th ed. Philadelphia: W.B.Saunders Company; 1998: 1266-9.
3. Johnston HC, Shigeoka AO, Hurley DC, Pysker TJ. *Nocardia* pneumonia in a neonate with chronic granulomatous disease. *Pediatr Infect Dis J* 1989; 8: 526-9.
4. Kim OH, Yang HR, Bahk YW. Pulmonary nocardiosis manifested as miliary nodules in a neonate: a case report. *Pediatr Radiol* 1992; 22: 229-30.
5. Singh NP, Goyal R, Manchanda V, Gupta P. Disseminated nocardiosis in an immunocompetent child. *Ann Trop Pediatr* 2003; 23: 75-8.
6. Sorrell TC, Iredell JR, Mitchell DH. Higher bacterial diseases: *Nocardia* species. In: Mandell GL, Bennett JE, Dolin R, eds. Principles and practice of infectious diseases. 5th ed. Philadelphia: Churchill Livingstone; 2000: 2637-45.
7. Lerner PI. Nocardiosis. *Clin Infect Dis* 1996; 22: 891-905.
8. American Academy of Pediatrics. Nocardiosis. In: Pickering LK, ed. 2000 Red Book: Report of the Committee on Infectious Diseases. 25th ed. Elk Grove Village, IL: American Academy of Pediatrics; 2000: 411-2.
9. Law BJ, Marks MI. Pediatric nocardiosis. *Pediatrics* 1982; 70:560-5.

ทารกแรกเกิดภูมิคุ้มกันปกติที่มีภาวะปอดอักเสบร่วมกับหนองในช่องเยื่อหุ้มปอดจากการติดเชื้อ *Nocardia*: รายงานผู้ป่วย

ทวิวงศ์ ต้นตราชีวิต, สมศักดิ์ โฉมเลขา, สุภาพรณ ต้นตราชีวิต

ผู้ป่วยทารกเพศชายอายุ 40 วัน มีไข้ ไอไม่มีเสมหะเป็นเวลา 3 สัปดาห์ หายใจหอบเหนื่อย 5 วันก่อนมาโรงพยาบาล ภาพรังสีทรวงอกและเอกซเรย์คอมพิวเตอร์ทรวงอกพบเงาที่ปอดด้านขวาร่วมกับ มีน้ำในช่องเยื่อหุ้มปอด เจาะช่องเยื่อหุ้มปอดพบหนองสีเหลือง ส่งเพาะเชื้อขึ้น *Nocardia asteroides* เอกซเรย์คอมพิวเตอร์สมอง และช่องท้อง ไม่พบสิ่งผิดปกติ รักษาโดยให้ trimethoprim 15 มก/กก/วัน ร่วมกับ sulfamethoxazole 75 มก/กก/วัน ทางหลอดเลือดดำเป็นเวลา 3 สัปดาห์ และรับประทานยาต่อในขนาดเดียวกันเป็นเวลา 6 เดือน ผลการทดสอบภูมิคุ้มกันชนิดฟิงเชลล์ และ anti-HIV อยู่ในเกณฑ์ปกติ ตรวจ flow cytometric assay โดยกระตุ้นด้วยเชื้อ *Staphylococcal aureus* และ phorbol myristate acetate (PMA) ได้ผลปกติ ซึ่งแสดงว่าความสามารถในการฆ่าเชื้อภายในเซลล์ของ PMN อยู่ในเกณฑ์ปกติ หลังรักษาครบกำหนดได้ติดตามผู้ป่วยเป็นเวลา 1 ปี พบว่าเด็กมีสุขภาพแข็งแรงดี ภาพรังสีทรวงอกอยู่ในเกณฑ์ปกติ