

Congenital tuberculosis presenting as sepsis syndrome

Chulapong Chanta MD*,
Yaowaluk Jariyapongpaibul MD*, Krilerk Triratanapa MD*

* Pediatric Unit, Chiang Rai Prachanukraw Hospital

A 20 day old male infant presented with fever, respiratory distress and poor feeding for 7 days. He was referred from a community hospital and diagnosed as sepsis. Physical examination revealed hepatosplenomegaly. A chest radiograph showed miliary infiltration of both lungs. Smear of gastric washing for AFB was positive. Congenital tuberculosis was diagnosed, the infant was successfully treated with antituberculous drugs and followed up monthly for 1 year. He had good health and normal development after the illness.

Keywords : Congenital tuberculosis, Sepsis, Antituberculous drugs

J Med Assoc Thai 2004; 87(5): 573-7

Tuberculosis remains a significant public health problem in Thailand and worldwide. Thailand is one of the countries that has an epidemic problem, because there is increasing in number of HIV infected patients especially in the upper northern region. The incidence of HIV infected tuberculosis patients is as high as 42.9% in some areas⁽¹⁾. The current situation of tuberculosis, WHO estimates that one third of the world population is infected with tuberculosis and the infection rate increases about 1% per year. WHO also estimates that by the year 2005, the number of tuberculosis patients will be highest in South East Asia amounting to 3.3 million cases⁽²⁾. In recent years, the number of tuberculosis cases has increased during the epidemic of HIV infection. Coinfection with HIV increases the likelihood of extrapulmonary tuberculosis⁽³⁾. Women of childbearing age who have HIV infection may, therefore, be at increased risk for placental or genital tuberculosis, resulting in an increased risk of congenital transmission. Nevertheless, congenital tuberculosis has been reported rarely as nonspecific clinical manifestations and asymptomatic mothers make it difficult to diagnosis. There are about 300 cases of congenital tuberculosis reported in the literature⁽⁴⁾. The authors report an infant with congenital tuberculosis who presented with sepsis. The diagnostic criteria for distinguishing congenital from postnatal acquired

tuberculosis and the literature on congenital tuberculosis were also reviewed.

Case Report

A 20 days old male infant presented with clinical sepsis. He had a 7 days history of fever, cough and poor feeding. Three days after the illness, he was admitted and treated with ampicillin plus gentamycin for 4 days. He did not respond to treatment and was thus transferred to Chiang Rai hospital. He was born at a community hospital by normal delivery. The birth weight was 2,560 gm., and Apgar scores were 8 and 9 at 1 and 5 minutes. He was separated from his mother after delivery due to maternal TB. He stayed with his grandmother and had formula feeding.

Physical examination revealed a lethargic infant with tachypnea and hepatosplenomegaly. A chest radiograph showed bilateral diffuse infiltration as shown in Fig. 1. The white blood cell count was 5,250/mm³ with 20% polymorphonuclear cells and 77% lymphocytes. The platelet count was 49,600/mm³ and the coagulogram showed prolonged PT and PTT of 42.6 and 60.8, respectively, suggesting disseminated intravascular coagulation (DIC). Gastric washing was positive for AFB (+1 → +2) for 3 consecutive days but culture for TB showed no growth. Serologic testing for HIV was negative. The cerebrospinal fluid was normal. Bacterial cultures of blood and CSF were negative. Mantoux skin test was negative. He was diagnosed with congenital tuberculosis and anti TB

correspondence to : Chanta C, Pediatric Unit, Chiang Rai Prachanukraw Hospital, Chiang Rai 57000, Thailand.

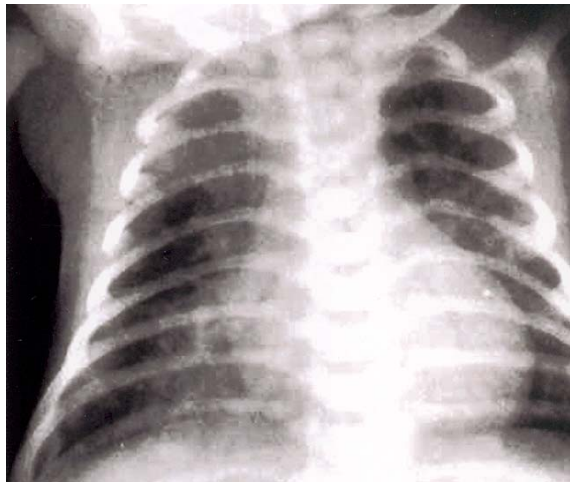


Fig. 1 CXR reveals diffuse bilateral interstitial infiltration of both lungs

drugs (INH, Rifampicin, PZA, Streptomycin) were started. Cefotaxime was also administered for 14 days, beginning on admission. One week after treatment, he developed jaundice, LFT showed elevation of bilirubin and liver enzymes; total bilirubin/direct bilirubin = 18.6/14.9, SGOT = 120 and SGPT = 79. Vitamin K 1 mg. was administered intravenous route. Rifampicin and PZA were discontinued and jaundice improved in 1 week.

Ciprofloxacin was substituted for rifampicin and the patient responded well to therapy. He was discharged on day 35 of admission. The patient was followed up monthly thereafter without exacerbation of his tuberculosis. His hepatosplenomegaly persisted and ultrasound abdomen at 10 months of age showed multiple calcifications at liver and spleen (Fig. 2). After treatment with anti TB drugs for 1 year (2ICS/10 IC), CXR showed clearing of miliary lesions in the lung.

He maintained good health and development during regular clinic visits.

His mother developed pain and swelling in the left ankle joint at 5 months of pregnancy and had symptomatic treatment. At delivery, she had purulent discharge from her left ankle. Left ankle x-ray and CXR showed diffuse osteoporosis with narrowing joint space and diffuse reticulonodular infiltration in both lungs, respectively as shown in Fig. 3 and 4. Pus examination for AFB was positive. She was diagnosed as tuberculous arthritis and treated with anti TB drugs for 9 months until she improved.

Discussion

Tuberculosis in the neonate can be either congenital (ie, acquired in utero) or neonatal (ie, acquired early in life from mother or contagious member). Hematogenous spread and aspiration of infected amniotic fluid account for approximately half the cases of congenital tuberculosis each^(4,5). In neonatal tuberculosis, infants can be acquired by inhalation or ingestion of infected droplet or by contamination of traumatized skin or mucous membranes. It is not always possible to be sure of the route of infection in a particular neonate, and with effective chemotherapy, it is not essential for the care of the infant. However, it is important to try to identify the source of infection so that the person infecting the infant can be treated and further transmission can be prevented.

In 1935, Beitzke⁽⁶⁾ suggested criteria for diagnosis of congenital tuberculosis. These criteria include confirmation of TB in the infant and one of the following; lesions in the first few days of life, demonstration of a primary hepatic complex, or exclusion of postnatal exposure by separation of the infant from mother at birth. Beitzke criteria have

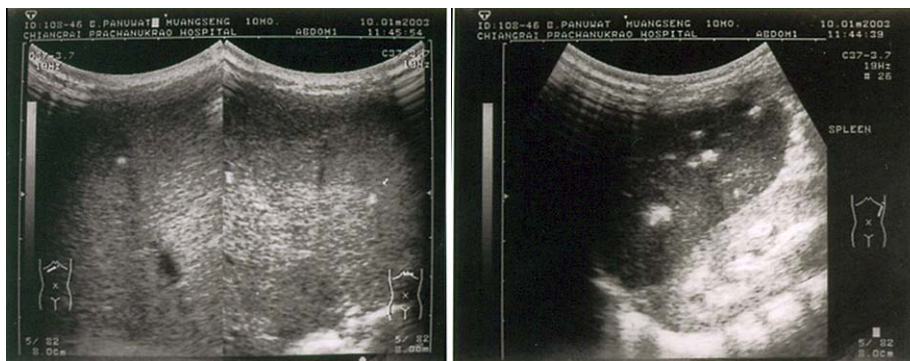


Fig. 2 Ultrasound abdomen reveals hepatosplenomegaly with multiple calcifications

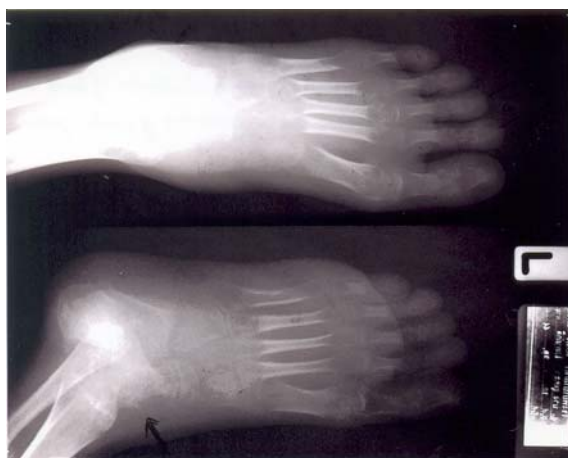


Fig. 3 Left ankle x-ray reveals destruction of bones with diffuse osteoporosis and narrowing of joint space.

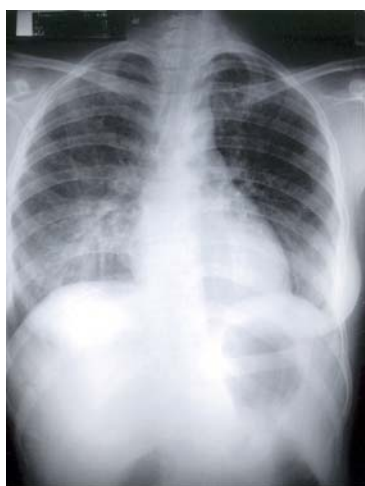

Fig. 4 CXR of the infant's mother. Diffuse reticulonodular infiltrations are evident in both lungs.

become difficult to apply in clinical practice because it must demonstrate the primary hepatic complex by surgical procedure or autopsy to confirm liver and regional lymph node involvement, in contrast with liver biopsy to demonstrate caseating hepatic granuloma which is more simplified. In addition, the infant must be separated from the mother at birth rather than a thorough investigation of contacts. So in 1994, Cantwell et al⁽⁴⁾ proposed the following revised diagnostic criteria; the infant must have a proven tuberculous lesion and at least one of the following; 1) lesion in the first week of life 2) a primary hepatic complex or caseating hepatic granulomas 3) tuberculosis infection of the placenta or maternal

genital tract 4) exclusion of postnatal transmission by a thorough contacts investigation. The authors consider the presented case involving miliary TB in an infant along with the separation of infant from mother to be highly suspicious for the diagnosis of congenital tuberculosis, according to Beitzke criteria. Although the gastric aspirate culture for TB showed no growth, a positive acid fast bacilli smear of an early morning gastric aspirate obtained from a newborn should be considered indicative of tuberculosis⁽⁶⁾. Hageman et al⁽⁸⁾ found positive cultures for *M. tuberculosis* in 9 of 12 gastric aspirates. In the presented case, the negative result may be from a technical problem in laboratory culture or collection of specimen.

Symptoms of congenital tuberculosis may present at birth but more commonly begin by the second or third week of life. In one series of 48 infants exposed postnatally to mothers with pulmonary tuberculosis in the pretreatment era, 21 became infected; of those who became ill; symptoms and signs developed in 4 to 8 weeks⁽³⁾. When considering the timing of presentation in the presented case which was about 2 weeks of age, it may be further evidence that suggests the diagnosis of congenital tuberculosis. The most frequent signs or symptoms of congenital tuberculosis are listed in Table 1⁽⁴⁾.

In the presented case, the authors found hepatosplenomegaly, respiratory distress, fever, lethargy compatible with previous studies^(5,6).

The diagnosis of congenital tuberculosis should be suspected in any infant with signs and symptoms of sepsis who does not respond to vigorous antibiotic therapy and whose is exclusive for congenital infection, especially if the mother has

Table 1. Most Frequent Signs and Symptoms of Congenital Tuberculosis

Symptom or Sign	Frequency (%)
Hepatosplenomegaly*	76
Respiratory distress*	72
Fever*	48
Lymphadenopathy	38
Abdominal distention	24
Lethargy or Irritability*	21
Ear discharge	17
Papular skin lesions	14
Vomiting, Apnea, Cyanosis, Jaundice, Seizure, Petichiae	< 10 each

* symptoms or signs found in the presented patient

tuberculosis or in the high risk group. The presented case was transferred with clinical sepsis and did not respond to antibiotic therapy and the mother developed tuberculosis at birth, so congenital tuberculosis was suspected initially. The diagnosis of maternal tuberculosis may be difficult if clinical manifestation of disease is extrapulmonary as in the presented case which was diagnosed at delivery. Screening for tuberculosis should be part of the routine prenatal examination especially in areas with an increasing incidence of infection with initiation of prompt treatment after diagnosis⁽⁹⁾. Recommendations of the American Academy of Pediatrics for management of infants born to women with tuberculosis are available in the Red Book⁽¹⁰⁾.

All children with suspected congenital tuberculosis should be started on four anti TB drugs⁽⁴⁾ (INH, RIF, PZA plus either Ethambutol or Streptomycin). Although the optimal duration of therapy has not been established, many experts treat infants with congenital or postnatal acquired tuberculosis for 9 to 12 months because of the low immunologic capability in young infants. It has previously been reported that patients with severe disease, especially miliary tuberculosis are more likely to have abnormalities of liver function⁽¹¹⁾. Thus, in our patient, hepatic involvement may either be from drug induced or severe disease potentiate drugs hepatotoxicity. In the presented patient, hepatosplenomegaly persisted with multiple calcifications as in one reported case from Nemir RL and O'Hare D⁽¹²⁾.

In summary, congenital tuberculosis is a rare disease that is difficult to diagnose because of minimal or no symptoms in the mother and nonspecific symptoms in the infant. A high index of suspicion is required for diagnosis. If congenital tuberculosis is suspected, full evaluation should include a Mantoux skin test, CXR and evaluation of gastric aspirates, CSF for presence of AFB. The presented patient demonstrates that congenital TB can have a presentation with clinical sepsis and prompt initiation

of antituberculous medications which lead to improved clinical outcome.

References

1. Karnkawinwong O. Effectiveness of antituberculosis drugs regimen 2 HRZES/1 HRZE/5 HRE. *Thai J Tuberc chest Dis.* 2002; 23: 107-14.
2. World Health Organization. WHO Report 2001, Global Tuberculosis Control: 18-19.
3. Barnes PF, Block AS, Davidson PT, Snider DE Jr. Tuberculosis in patients with human immunodeficiency virus infection. *N Engl J Med.* 1991; 324: 1644-50.
4. Starke JR, Smith MHD. Tuberculosis. Infectious disease of the fetus and newborn infant. 5th Edition. Philadelphia: WB. Saunders Company 2001, 1179-97.
5. Cantwell MF, Shehab ZM, Castello AM, et al. Brief report: congenital tuberculosis. *N Engl J Med.* 1994, 330(15): 1051-4.
6. Mazade MA, Evans EM, Starke JR, et al. Congenital tuberculosis presenting as sepsis syndrome. Case report and review of the literature. *Pediatr Infect Dis J.* 2001; 20: 439-42.
7. Klotz SA, Penn RL: Acid fast staining of urine and gastric contents is an excellent indication of mycobacterial disease. *Am Rev Respir Dis.* 1987, 136: 1197-8.
8. Hageman J, Shulman S, Schreiber M, et al. Congenital tuberculosis: Critical reappraisal of clinical findings and diagnostic procedures. *Pediatrics* 1980, 66: 980-4.
9. Abughali N, Van der Kuyp F, Annable W, et al. Congenital tuberculosis. *Pediatr Infect Dis J.* 1994, 13: 738-41.
10. American Academy of Pediatrics. Tuberculosis. In: Pickering LK, ed 2000 Red Book: Report of the Committee on Infectious Diseases. 25th ed. Elk Grove Village, IL: American Academy of Pediatrics, 2000: 593-613.
11. Korn RJ, Kellow WF, Heller P, et al. Hepatic involvement in extrapulmonary tuberculosis: Histologic and functional characteristics. *Am J Med.* 1959; 27: 60-71.
12. Nemir RL, O'Hare D. Congenital tuberculosis. Review and diagnostic guidelines. *Am. J Dis Chil.* 1985; 139: 284-7.

วัณโรคแต่กำเนิดที่มาด้วยอาการแบบเช็พลิส

จุลพงษ์ จันทรตะ, เขาวลัษณ์ จริยพงษ์ไพบูลย์, ไกรฤกษ์ ไตรรัตนภา

รายงานผู้ป่วยเด็กทารกเพศชาย อายุ 20 วัน ได้รับการส่งต่อมาจากโรงพยาบาลชุมชน ด้วยภาวะ เช็พลิส โดยมีอาการไข้ หายใจลำบาก ตู่นมน้อยลง 7 วัน การตรวจร่างกายพบมีตับ ม้ามโต การตรวจภาพรังสีปอด พบมี military infiltration ในปอด 2 ข้าง การตรวจน้ำล้างกระเพาะ ย้อม AFB ให้ผลบวก ผู้ป่วยได้รับการวินิจฉัยเป็น วัณโรคแต่กำเนิด และให้การรักษาด้วยยาต้านวัณโรค เป็นเวลา 1 ปี ระหว่างรักษาได้ติดตามอาการทุกเดือน ผู้ป่วยตอบสนองดีต่อการรักษา โดยไม่มีการกำเริบของวัณโรค ผู้ป่วยมีสุขภาพแข็งแรงและพัฒนาการสมวัย ระหว่างที่มารับการตรวจติดตามที่แผนกผู้ป่วยนอกโรงพยาบาลเชียงใหม่
