

Percutaneous versus Open Bone Grafting in the Treatment of Tibial Fractures: A Randomized Prospective Trial

Jakravoot Maneerit MD*,
Surapoj Meknavin MD*, Sukit Hanpanitkitkan MD*

* Department of Orthopaedic Surgery, Bangkok Metropolitan Administration Medical College and Vajira Hospital

Purpose : To compare the results between percutaneous bone grafting and open bone grafting of tibial shaft fractures.

Method : Thirty tibial fractured shafts with a delayed union or a high-energy tibial fractures which required early prophylaxis bone grafts were randomized to either percutaneous bone graft (n=15) or open bone graft (n=15). One patient from the open bone graft group was lost to follow-up. Characteristics of the patients were similar in both groups.

Results : The mean length of follow-up was 2.5 years. Percutaneous bone graft technique was associated with significantly less blood loss ($p<0.01$) and shorter operative time ($p<0.01$). One patient in the percutaneous group had posterior tibial nerve palsy postoperatively, which recovered completely after 6 weeks. There were no differences in rate of union, healing time of the successful cases, postoperative pain and hospital stay.

Conclusion : The percutaneous technique has effective results similar to the open technique in promoting union of tibial fractures. It should be considered as a useful alternative to the open bone graft technique.

Keywords : Bone graft, Percutaneous, Fracture tibia

J Med Assoc Thai 2004; 87(9): 1034-40

Tibial fracture is a relatively common fracture which may be complicated by delayed union and non-union, especially in high-energy trauma. There is a report which indicated that 20% to 70% of high-energy tibial fractures requires bone graft to achieve bony union⁽¹⁾. Open bone grafting is indicated for the treatment of delayed union, non-union and also for early prophylactic bone grafting of high-energy tibial fractures⁽²⁾. Early bone grafting at 6 to 8 weeks post injury is well-accepted as a method to increase the union rate and shorten the union time⁽²⁾. Despite good visualization to the non-union site in open bone graft technique, it has the disadvantage of disturbance of blood supply to the bone, overlying skin graft or pedicle flap which resulted in skin necrosis, delayed

healing and infection. Several techniques for minimally invasive bone grafts have been reported^(3,5). Percutaneous bone grafting has reported a high success rate without complications^(3,4). Bhan and Mehara⁽³⁾ used two cores of bones from the iliac crest across the non-union. Kettunen et al⁽⁴⁾ used one or 2 pieces of bone graft driven into the hole, crossing perpendicular to the fracture line, and under fluoroscopic control. Johnson et al⁽⁵⁾ applied an arthroscope to the nonunion site, debridement fibrous union and performed transcuteaneous autogenous bone graft. They packed the bone graft into the area of bone deficiency. Connolly et al⁽⁶⁾ used a large amount of autogenous bone marrow from the patient's iliac crest and injected it directly percutaneously into the fracture site. Most of the studies concluded that the percutaneous technique appeared to be as effective as the open techniques, saving operative time and shortening hospital stay^(3,4). However, there has been no study comparing percutaneous bone grafting and open bone grafting of tibial shaft fractures. The authors present a comparison of the

Correspondence to : Maneerit J, Department of Orthopaedic Surgery, Bangkok Metropolitan Administration Medical College and Vajira Hospital, Samsen Rd, Dusit, Bangkok 10300, Thailand. Phone: 0-2244-3376, E-mail: maneerit@hotmail.com

percutaneous technique with the open technique in tibial shaft fractures.

Patients and Method

From October 1998 to June 2001, thirty patients with tibial shaft fractures that required bone grafting were prospectively randomized into two treatment groups. They were assigned to either percutaneous bone grafting or open bone grafting. The inclusion criteria in the present study were non-union which had not healed after 9 months, delayed union which had not healed after 3 months. The potential delayed union in Gustilo⁽⁷⁾ type III open fractures without radiographic sign of callus formation after 6 weeks, which required early prophylactic bone grafting at 6 to 12 weeks were also included. Out of 30 patients, 15 required bone grafting for delayed union and 15 required prophylactic bone grafting. There was no non-union tibial fracture in the present study. In cases with previous open fractures, bone grafting was performed after soft-tissue coverage had been performed without infection. The patients with a bone defect more than 2.5 cm, associated with severe complex intra-articular fracture, active infection at the fracture site, failure from previous operative bone grafting and patients less than 18-years-old were excluded. All patients in this study gave informed consent. Patients were randomly assigned either to percutaneous bone grafting or open bone grafting by a computer program. Of the total 30 patients, one case in the open group was lost to follow-up at 3 months after prophylactic bone grafting and was excluded, leaving 29 patients for analysis. The percutaneous group had 15 patients and the open group had 14 patients. Demographic data of the two groups is shown in Table 1. The types of initial injury and fracture are shown in Table 2. The

authors found no significant differences between these two groups. The mean length of follow-up was 30 months (range, 12-46 months) in the percutaneous group and 32 months (range, 25-52 months) in the open group.

Operative technique

All procedures were performed under general or spinal anaesthesia with tourniquet control. An 8-mm hollow cylindrical cutter (Fig. 1) was used to obtain ten pieces of a cancellous bone graft from the anterior iliac crest through a 5-cm incision. The cutter helped to accurately measure the size of the graft, which was 3-4 cm in length. The patients in percutaneous group were placed in supine position under an image intensifier. A longitudinal 1.5 cm incision was made between the tibia and fibula over the fracture site. The trocha with protection sleeve (Syntes, Mathys Medical Ltd. Switzerland) for the locking screw of the interlocking nail was introduced into the fracture gap under an image intensifier (Fig. 2). Latero-medial direction was used to avoid penetration into the posterior compartment. The trocha was then replaced with an 8-mm drill bit. The fracture was drilled to remove some parts of the fibrous tissue from the fracture gap and open the medullary canal. The cortical raw surface of bone adjacent to the fracture site was also drilled to promote bone graft incorporation. Ten pieces of graft were then driven into and around the fracture site (Fig. 2). The incision was closed.

The open bone grafting technique was carried out in a standard fashion. The choices of incision depended on the condition of overlying soft tissues. The incision was anterior in seven patients. A posterolateral Harmon approach was used in the remaining 7 patients who had a scar or skin graft at

Table 1. Demographic characteristics data of percutaneous bone graft and open bone graft groups

Characteristic	Percutaneous group (n=15)	Open group (n=14)	P-value
Mean age (yr)	33 (range, 18-67)	32 (range, 18-65)	NS
Male : Female	13 : 2	13 : 1	
Mean time injury to bone grafting (wk)	12 (range, 6-32)	11 (range, 6-17)	NS
Stabilization before bone grafting			
Plate	1	3	-
Nail	1	1	-
External fixation	13	10	NS
Indication for bone graft			
Delay union	8	7	NS
Prophylactic	7	7	NS

NS = no significant difference

Table 2. Types of initial injury and fractures of the patients

Type of initial injury	Percutaneous group (n=15)	Open group (n=14)	P-value
Mechanism of injury			
Road-traffic accidents	14	13	NS
Fall from a height	1	0	NS
Mean injury severity score ⁽¹⁷⁾	17 (range, 9-27)	15 (range, 9-25)	NS
Soft-tissue injury by Gustilo classification ⁽⁷⁾			
Closed fracture	1	1	NS
Open Type I	0	2	NS
Open Type II	1	0	NS
Open Type III-A	12	11	NS
Open Type III-B	1	0	NS
AO classification type ⁽¹⁸⁾			
A Simple	0	3	NS
B Butterfly	12	10	NS
C Comminuted	3	1	NS
Bone loss in cortical circumference			
<50%	7	8	NS
>50%	8	6	NS

NS = no significant difference between two group

the anterior border of the leg. A longitudinal 10 cm incision was made. The fracture site was exposed subperiosteally and fibrous tissue was removed. Ten pieces of autogenous bone graft were placed at the fracture site. The incision was closed over a vacuum drain. No further bony procedure was performed. All patients received prophylactic antibiotics.

Postoperatively, patients with internal fixation were mobilized with non-weight bearing for 6 weeks or more; depending on evidence of callus formation on radiographs. Partial weight bearing was started when the radiograph showed some evidence of callus formation. Full weight bearing was allowed when adequate bridging callus was visible on the




Fig. 1 Photograph showing an 8 mm hollow cylindrical cutter (a) with an expulsion piston (b), designed by the author

radiographs. Patients with external fixation were mobilized with non-weight bearing until adequate bridging callus. The external fixator clamp was loosened for 14 days to allow full weight bearing before removal of the external fixator. If there was no pain on full weight bearing the external fixator was removed. Radiographs were taken every six weeks postoperatively until the fracture showed radiographic union. Union was defined as adequate bridging callus on radiographs, no pain

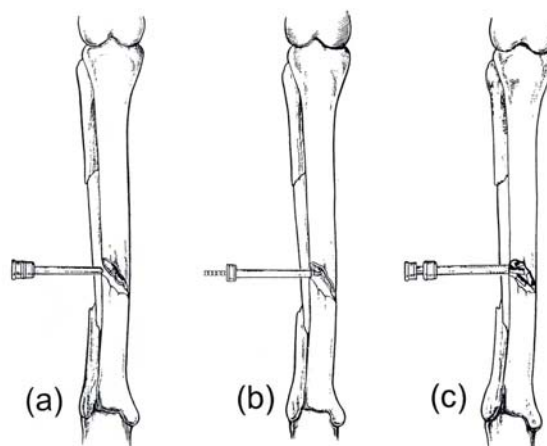


Fig. 2 Diagram showing sequence of the percutaneous bone grafting technique. The trocha with a protective sleeve was introduced into the fracture site under an image intensifier (a). The trocha was replaced with an 8-mm drill bit, which was used to create a raw surface by drilling into and around the fracture site (b). Ten pieces of graft were placed at the fracture site through the sleeve (c).

at the fracture site on weight bearing and stable while bending the leg. Malalignment was defined when the fracture had more than 5° of varus or valgus angulation, more than 10° of anteroposterior angulation, more than 10° of malrotation or shortening of more than one centimeter⁽⁸⁾. A non-union was defined as a failure of union of the fracture by 9 months⁽⁸⁾.

All patients were operated on and reviewed by one author (JM). The data recorded for all patients included surgical time, postoperative blood loss, and pain visual analogue scale (0, none to 10, severe) on the first day and length of hospital stay. Success of union, time to achieve radiographic union and complications were recorded. Statistical analysis was performed using SPSS version 11.0 (SPSS Inc, Chicago, Illinois). Student's t test, Mann-Whitney U test and Fisher's exact tests were used where appropriate. A p-value of less than 0.05 was considered statistically significant.

Results

The mean total surgical time was 37 minutes (range, 25-60 minutes) for the percutaneous group and 51 minutes (range, 35-70 minutes) for the open group ($p < 0.01$, $\alpha = 0.05$, power = 86%) (Table 3). In the percutaneous group, mean postoperative estimated blood loss was 9 mL (range, 0-20 mL), whereas patients in the open group lost 80 mL (range, 5-270 mL) via vacuum drain. The difference between the two groups was highly significant ($p < 0.01$). The pain scales on the first post operative day were 4 for the percutaneous group and 5 for the open group, which were not statistically significant ($p = 0.12$). The percutaneous group spent an average of 2.6 days in the hospital, slightly shorter than the average of 3.3 days in the open group, but not statistically significant ($p = 0.13$). The percentage of united fracture was similar in both groups ($p = 0.68$). The percutaneous group

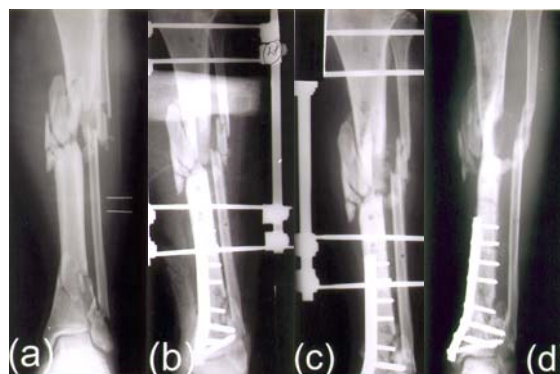


Fig. 3 A leg, tibial radiographs of a 41-year-old man who sustained a Grade III-A open segmental fracture (a). Eight weeks after the injury (b), the early prophylactic bone grafting at the comminuted segmental fracture was performed by percutaneous technique (c). Union was achieved at 18 weeks after the procedure (d).

achieved union in 12 out of 15 (80%) patients (Fig. 3) and the open group achieved union in 10 out of 14 (71%) patients. The average time to radiographic union was 15 weeks (range, 12-20 weeks) in the percutaneous group and 15 weeks (range, 12-20 weeks) in the open group ($p = 0.84$).

The three patients, who were unsuccessful in the percutaneous group, were type III-A tibial fractures with external fixators. All of them defined unsuccessful with false movement after removal of the external fixator at an average of 17 weeks (range, 15-18 weeks) postoperatively. All required a secondary procedure and went on to union. All patients underwent reamed tibial nailing and autogenous bone grafting and union was achieved. Four patients in the open group were unsuccessful at an average of 33.5 weeks (range, 17-48 weeks) postoperatively. One of these was a closed fracture with a broken intramedullary nail at 48 weeks after bone graft and was treated by

Table 3. Comparison of the outcome in both groups

Outcome	Percutaneous group (n=15)	Open group (n=14)	P-value
Surgical time (min)	37 (range, 25-60)	51 (range, 35-70)	<0.01*
Post operative bleeding (mL)	9 (range, 0-20)	80 (range, 5-270)	<0.01
Pain visual analogue scale at 1st day post operative	4 (range, 1-10)	5 (range, 2-10)	=0.12
Hospital stay (d)	2.6 (range, 1-4)	3.3 (range, 1-6)	=0.13*
Success of union	12	10	=0.68
Average time of union of success cases (wk)	15 (range, 12-20)	15 (range, 12-20)	=0.84
Malunion	2	3	=0.65
Complication	1	0	=1.0

* Student's t test; Mann-Whitney U test; Fisher's exact tests

plate fixation and bone grafting. Three of four patients were type III-A stabilized with the external fixator and had false movement at fracture sites after removal of the external fixators. Two patients, unsuccessful in the open group, were treated by intramedullary nail and bone grafting and the final patient was treated by plate fixation and bone grafting. All of these patients achieved union after the second procedure. Malunion was seen in two patients in the percutaneous group and in three in the open group. No patient in either group had shortening or rotational deformity. One patient of the percutaneous group had postoperative nerve palsy of the posterior tibial nerve, which recovered completely within 6 weeks. There were no wound complications.

Discussion

Open bone grafting is accepted as a treatment method for promoting union in nonunion, delayed union or prophylactic bone graft in high-energy tibial fracture^(2,9). Using the cortico-cancellous bone chips resulted in a shorter healing time, compared to a non-vascularized fibular graft or a massive corticocancellous bone block⁽¹⁰⁾. Autogenous bone graft obtained from the iliac crest is currently the gold standard among graft materials⁽¹¹⁾.

Many surgical approaches of bone grafting for the tibia have been described. Anterior approach is easily exposed to the tibia but it has limitations in case of an anterior scar or muscle flap and can cause skin or flap necrosis. The posterolateral approach has many advantages for avoidance of compromised anterior soft tissues, placement of the graft in a well vascularized area for rapid graft incorporation, and ability to place a large amount of graft⁽¹⁾. The medial approach can cause anterior soft tissue problems as an anterior approach. However, it can be easily applied for a fracture at the proximal one-fourth of the tibia, whereas the posterolateral approach cannot be performed. The lateral approach of Rijnberg⁽¹²⁾ can create central bridging callus between tibia and fibula. However, the deep peroneal nerve and the anterior tibial vessels may be injured by this procedure. The results of open bone grafting of un-united tibial fractures have reported a union rate ranging from 70 to 90%⁽¹³⁻¹⁵⁾. The minimally invasive bone grafting techniques in promoted union in the tibial fractures have been reported in many studies. Ebraheim et al⁽¹⁶⁾ uses paste bone graft injected at the fracture site through a rigid plastic tube and trocha under image intensifier. They showed union in their first case report. Bhan and

Mehara⁽³⁾ used a specially devised milling cutter for the insertion of two cores of bones from the iliac crest across the nonunion. They reported union during a period of 3 to 5 months in 18 out of 21 patients. Kettunen et al⁽⁴⁾ used an 8-mm cylindrical cutter to obtain a bone graft from the iliac crest and inserted a single graft across the fracture line. Thirty-seven of the 41 un-united fractures healed in 13 weeks (range, 10-48 weeks). Johnson et al⁽⁵⁾ applied arthroscopic techniques to autogenous bone grafting of long bone fractures with delayed union. A minimal soft-tissue debridement was performed to remove fibrous tissue from the nonunion site. Specialized instrumentation, a Bone Grafting, facilitated the transcutaneous means of harvesting and placement of the graft. The bone defects were packed with graft and extended 1 inch proximal and distal to the delayed union site. There were nine patients in this initial series, including four patients with humeral lesions and five patients with tibial fractures. Bony union occurred in all but one patient with humeral nonunion in an average of 4 months.

In the present study the authors used a percutaneous method with a trocha and protection sleeve for a locking screw insertion of an interlocking nail, instrument set which is easily available in the operating room. A minimal soft tissue debridement by an 8-mm drill bit was performed to remove fibrous tissue and opening the medullary canal. The authors used ten pieces of graft, adequate for a small bone gap, filled at the fracture gap on the lateral side, which gave better vascularization than the medial side. A cylindrical cutter helped to estimate the amount of bone graft equally in both groups. One can use a cortico-cancellous bone chip graft from an iliac crest without a cylindrical cutter as a standard technique inserting into the protection sleeve. Although various techniques of minimal invasive bone grafting have been reported, the main advantages of the principle include minimal trauma, short operative time and less blood loss.

The present results have confirmed these advantages of the shorter operative time, less blood loss and as effective as the open technique. Ten pieces of graft that were packed into the fracture gap in the percutaneous group can cause elevated pain score and prolong hospital stay. A small volume of graft in the small un-united gap may decrease the pain score and hospital stay. A potential disadvantage of the percutaneous technique is its blind nature even though under an image intensifier. Therefore, one could cause damage to nerves. The posterior tibial nerve lies close

to the posterior surface of the distal tibia in the posterior compartment of the tibia and passes through a fixed fibrous tunnel located behind the bone on the inside of the ankle. This can cause the nerve to be vulnerable to injury easily. It is, therefore, important to hold the tip of the trocha not penetrating into the posterior compartment. The trocha was inserted from lateral to medial. The posterior direction should be avoided especially at the distal part of the tibia. However, posterior tibial nerve injury was rarely found in the open procedure^(10,13). The main disadvantages of the study, the small sample size and unavailable non-union, are mainly due to stringent inclusion criteria which contributed to the difficulty of recruiting a larger number of patients.

The present series showed shorter operative times and less blood loss using percutaneous bone grafting. The rate of union, union time, lengths of hospital stay and postoperative pain were not different in both groups. The percutaneous technique is a simple technique under an image intensifier intra-operatively. It should be considered as a useful alternative to the conventional bone grafting technique.

No benefits in any form have been received or will be received from a commercial party related directly or indirectly to the subject of this article.

References

1. French B, Tornetta P III. High-energy tibial shaft fractures. *Orthop Clin North Am* 2002; 33: 211-30.
2. Blick SS, Brumback RJ, Lakatos R, Poka A, Burgess AR. Early prophylactic bone grafting of high-energy tibial fractures. *Clin Orthop* 1989; 240: 21-41.
3. Bhan S, Mehara AK. Percutaneous bone grafting for nonunion and delayed union of fractures of the tibial shaft. *Int Orthop* 1993; 17: 310-2.
4. Kettunen J, Makela EA, Turunen V, Suomalainen O, Partanen K. Percutaneous bone grafting in the treatment of the delayed union and non-union of tibial fractures. *Injury* 2002; 33: 239-45.
5. Johnson LL, Morrison KM, Wood DL. The application of arthroscopic principles to bone grafting of delayed union of long bone fractures. *Arthroscopy* 2000; 16: 279-89.
6. Connolly JF, Guse R, Tiedeman J, Dehne R. Autologous marrow injection as a substitute for operative grafting of tibial nonunions. *Clin Orthop* 1991; 266: 259-70.
7. Gustilo RB, Mendoza RM, Williams DN. Problems in the management of type III (severe) open fractures: a new classification of type III open fractures. *J Trauma* 1984; 24: 742-6.
8. Helfet DL, Jupiter JB, Gasser S. Indirect reduction and tension-band plating of tibial non-union with deformity. *J Bone Joint Surg [Am]* 1992; 74A: 1286-97.
9. Thakur AJ, Patankar J. Open tibial fractures. Treatment by uniplanar external fixation and early bone grafting. *J Bone Joint Surg [Br]* 1991; 73B: 448-51.
10. Simon JP, Stuyck J, Hoogmartens M, Fabry G. Posterolateral bone grafting for nonunion of the tibia. *Acta Orthop Belg* 1992; 58: 308-13.
11. Khan SN, Tomin E, Lane JM. Clinical applications of bone graft substitutes. *Orthop Clin North Am* 2000; 31: 389-98.
12. Rijnberg WJ, van Linge B. Central grafting for persistent nonunion of the tibia. A lateral approach to the tibia, creating a central compartment. *J Bone Joint Surg [Br]* 1993; 75B: 926-31.
13. Reckling FW, Waters CH3. Treatment of non-unions of fractures of the tibial diaphysis by posterolateral cortical cancellous bone-grafting. *J Bone Joint Surg [Am]* 1980; 62A: 936-41.
14. Brighton CT, Shaman P, Heppenstall RB, Esterhai JL Jr, Pollack SR, Friedenber ZB. Tibial nonunion treated with direct current, capacitive coupling, or bone graft. *Clin Orthop* 1995; 321: 223-34.
15. Gershuni DH, Pinsker R. Bone grafting for nonunion of fractures of the tibia: a critical review. *J Trauma* 1982; 22: 43-9.
16. Ebraheim NA, Fenton PJ, Jackson WT. Percutaneous bone graft of the tibia. *J Orthop Trauma* 1991; 5: 83-5.
17. Baker SP, O'Neill B, Haddon W Jr, Long WB. The injury severity score: a method for describing patients with multiple injuries and evaluating emergency care. *J Trauma* 1974; 14: 187-96.
18. Muller ME, Allgower M, Schneider R, Willenegger H. Techniques recommended by the AO-ASIF group: manual of internal fixation, 3rd ed. Berlin: Springer-Verlag, 1991:1-158.

การปลูกกระดูกแบบเจาะผ่านผิวหนังและแบบเปิดแผล ในการรักษากระดูกที่เปื้อนหัก: การศึกษาแบบสุ่ม

จักรวรรธ มณีฤทธิ์, สุรพจน์ เมฆนาวิน, สุกิจ หาญพานิชกิจการ

วัตถุประสงค์ : เพื่อเปรียบเทียบผลระหว่างการผ่าตัดปลูกกระดูกแบบเจาะผ่านผิวหนังและแบบเปิดแผลในการรักษากระดูกที่เปื้อนหัก

วิธีการ : กระดูกที่เปื้อน 30 รายที่มีการติดเชื้อ หรือกระดูกที่เปื้อนหักอย่างรุนแรง ที่จำเป็นต้องทำการปลูกกระดูกในระยะแรก เพื่อป้องกันกระดูกติดเชื้อ ได้ถูกสุ่มโดยปลูกกระดูกแบบเจาะผ่านผิวหนัง (15ราย) หรือผ่าตัดปลูกกระดูกแบบเปิดแผล (15ราย) ผู้ป่วย 1 รายในกลุ่มที่ผ่าตัดไม่สามารถติดตามผลได้ ลักษณะของผู้ป่วยเหมือนกันทั้ง 2 กลุ่ม

ผลการศึกษา : การติดตามผลเฉลี่ย 2.5 ปี การใช้เทคนิคเจาะผ่านผิวหนังพบว่ามีส่วนสัมพันธ์กับการเสียเลือดน้อยลง ($p < 0.01$) และระยะเวลาในการผ่าตัดสั้นกว่า ($p < 0.01$) อย่างมีนัยยะสำคัญ ผู้ป่วย 1 รายในกลุ่มที่เจาะผ่านผิวหนัง หลังผ่าตัด มีอาการอัมพาตของเส้นประสาท posterior tibial ซึ่งฟื้นตัวอย่างสมบูรณ์หลัง 6 สัปดาห์ ไม่พบความแตกต่างในอัตราการติดเชื้อของกระดูก ระยะเวลาในการติดเชื้อของกระดูกในผู้ป่วยที่ประสบผลสำเร็จ อาการปวดหลังผ่าตัด และระยะเวลาในการอยู่โรงพยาบาล

สรุป : เทคนิคการเจาะผ่านผิวหนัง ให้ผลใกล้เคียงกับเทคนิคการผ่าตัดเปิดแผลในการส่งเสริมการติดของกระดูกที่เปื้อนหัก อาจพิจารณาได้ว่าเป็นทางเลือกที่เป็นประโยชน์อีกทางหนึ่งนอกเหนือจากเทคนิคการปลูกกระดูกแบบเปิดแผล
