

Preoperative Chemoradiotherapy in Locally Advanced Rectal Cancer: Ramathibodi Experience

Ekaphop Sirachainan, MD*,
Kanit Sumboonnanonda, MD**, Somjai Dangprasert, MD***,
Ravat Panvichian, MD*, Thitiya Sirisinha, MD*,
Mantana Dhanachai, MD***, Virat Pairachvet, MD***,
Puangtong Kraiphikul, MD***, Vorachai Ratanatharathorn, MD*

* Department of Medicine, Faculty of Medicine, Ramathibodi Hospital, Mahidol University

** Department of Surgery, Faculty of Medicine, Ramathibodi Hospital, Mahidol University

*** Department of Radiology, Faculty of Medicine, Ramathibodi Hospital, Mahidol University

A retrospective study of the preoperative chemoradiotherapy in locally advanced rectal cancer performed at Ramathibodi Hospital. The median age of twelve patients was 52 years. The tumor locations (upper-, mid-, lower rectum) were 25%, 50% and 25%, respectively. Eleven patients had clinical stage III disease. All received concurrent 5-FU-based chemoradiotherapy followed by surgery (if resectable) and chemotherapy. The most common toxicity of preoperative treatment was gr.1-2 diarrhea (58.3%). The response rate was 41.7%. Five patients (41.7%) underwent sphincter-sparing surgery. Four patients underwent AP resection. Twenty-five percent achieved pathological complete response. Pathological downstaging occurred in 33.3%. The remaining three patients had unresectable disease. With the median follow up of 13 months, five patients had progressive disease and one has expired. The local failure rate was 16.7%. The one-year recurrence-free survival was 75%. The authors conclude that preoperative chemoradiotherapy is an effective treatment with favorable outcome in locally advanced rectal cancer.

Keywords: Preoperative chemoradiotherapy, Locally advanced rectal cancer, Sphincter-sparing surgery

J Med Assoc Thai 2005; 88(2): 162-7

Full text. e-Journal: <http://www.medassocthai.org/journal>

After curative surgery of locally advanced rectal cancer (stage II T3-4 and stage III), the risk of recurrence is substantial because of microscopic residual disease. Postoperative adjuvant or preoperative neoadjuvant therapy is an attempt to minimize this risk. Therefore the two conventional treatments for locally advanced rectal cancer consist of surgery followed by postoperative combined modality therapy known as standard adjuvant therapy and preoperative combined modality therapy followed by surgery and postoperative chemotherapy.

The standard adjuvant chemoradiotherapy has been demonstrated in a randomized trial to provide a prolongation of survival and a reduction of local recurrence⁽¹⁾. The preoperative treatment is

increasingly accepted as a novel standard therapy. Preoperative radiotherapy alone has been proved to reduce the local recurrence rate and improve overall survival⁽²⁾. The preoperative chemoradiotherapy has been evaluated in many phase II-III trials⁽³⁻¹⁵⁾. By downstaging the tumor with a preoperative treatment, many patients can avoid having permanent colostomy and have a sphincter preservative surgery performed.

At Ramathibodi Hospital, the multi-modality team consists of medical oncologists, surgical oncologists, radiation oncologists, radiologists, pathologists and nurses. The authors reviewed mostly complicated or problematic cancer cases, including those with locally advanced rectal cancer. The preoperative chemoradiotherapy approach has been performed at this hospital for at least 5 years.

Correspondence to : Sirachainan E, Department of Medicine, Faculty of Medicine, Ramathibodi Hospital, Mahidol University, Bangkok 10400, Thailand.

Material and Method

The medical records of a group of patients with locally advanced rectal cancer who underwent preoperative chemoradiotherapy at Ramathibodi Hospital between August 1998 and October 2003 were reviewed. All patients had abdominal CT scan performed before the treatment was begun. All received preoperative 5-FU-based chemotherapy (5-FU with or without leucovorin) concurrently with pelvic radiotherapy. Post-treatment evaluation by abdominal CT scan was performed 5-6 weeks after completion of radiotherapy. A curative surgical resection was performed in patients who were deemed respectable, with sphincter preservation done whenever possible. Following the surgery or chemoradiotherapy (in unresectable cases), adjuvant 5-FU-based chemotherapy was given. After completion of the treatment, all patients were under surveillance periodically.

Each patient's information including age, sex, histology and differentiation of the tumor, location of tumor, pretreatment staging (cT, cN), preoperative treatment (type, dosage, and cycle of chemotherapy, dose of radiotherapy), postcombined-modality treatment assessment, date and type of surgery, pathological staging (pT, pN), postoperative chemotherapy, date and site of recurrence and date of last follow up or death were collected for analysis. The location of the tumor was defined as upper, mid or lower rectal if the tumor was located at >10 cm, 5-10 cm or <5 cm from the anal verge, respectively.

The clinical response categories are defined as follows:

- Complete response (CR): the disappearance of all target lesions with no new lesions forming
- Partial response (PR): at least a 50% decrease in the volume of target lesions
- Stable disease (SD): the target lesions have neither sufficiently shrunk to qualify for PR, nor sufficiently increased in size to qualify for PD
- Progressive disease (PD): at least a 25% increase in the volume of target lesions or the appearance of one or more new lesions

The recurrence-free survival and overall survival were defined as the durations from the date preoperative treatment was started to the date the patient developed recurrence disease or died, respectively.

Results

Twelve cases of locally advanced rectal cancer patients who underwent a preoperative chemo-

radiotherapy were identified and their medical records were reviewed. The pretreatment patients' characteristics are shown in Table 1.

Eight patients (67%) were male. The median age was 52 years (range 34-75 years). All patients had histological diagnosis of adenocarcinoma, mostly with well differentiation (92%). Only one patient (8%) had poorly differentiated adenocarcinoma. The tumor locations were 25% lower rectum, 50% mid rectum and 25% upper rectum. Eleven patients (92%) had pretreatment clinical stage III (cT3-4cN1-2cM0) while another patient (8%) had stage II (cT4cN0cM0) disease. Three patients had cT4cN0-1 disease, which seemed to be unresectable.

During concurrent chemoradiotherapy, all patients received 1-2 cycles of chemotherapy and at least 4,500 cGy of pelvic radiotherapy followed by the 3rd cycle prior to the assessment. The most common toxicity of preoperative treatment was gr 1-2 diarrhea (58.3% of all patients). The other toxicities, mostly gr 1-2, were nausea, vomiting, mucositis and infection (urinary tract infection, herpes simplex infection). All toxicities were manageable.

After completion of preoperative chemoradiotherapy, the abdominal CT scans of eleven patients were done. The response rate was 41.7% (five patients achieved clinical partial response) as demonstrated in Table 2.

Three patients (25%) had stable disease. Four patients (33.3%) had progressive disease. One of them

Table 1. Patients' characteristics

Characteristics	n	Percents
Number of patients	12	100.0
Male	8	66.7
Female	4	33.3
Median age (years)	52	
Range (years)	34-75	
Histology: Adenocarcinoma	12	100.0
Well differentiated	11	91.7
Poorly differentiated	1	8.3
Location: Upper rectum	3	25.0
Midrectum	6	50.0
Lower rectum	3	25.0
Clinical stage II	1	8.3
Clinical stage III	11	91.7
cT2	1	8.3
cT3	8	66.7
cT4	3	25.0
cN0	1	8.3
cN1	10	83.4
cN2	1	8.3

Table 2. The pretreatment staging, clinical response assessment after preoperative chemoradiotherapy and pathological staging of individual patient

Patient no.	Initial	cT	cN	Clinical response*	pT	pN
1	CJ	2	1	PD	0	1
2	SS	3	1	SD	3	1
3	JS	3	1	PR	3	1
4	VV	3	1	SD	2	0
5	AO	3	1	PR	0	0
6	KP	3	1	PD	0	0
7	PN	3	1	PR	0	0
8	VP	3	1	PD	na	na
9	AK	3	2	PR	3	0
10	SP	4	0	PD	na	na
11	BV	4	1	PR	3	0
12	PT	4	1	SD	na	na

Note: Patients no. 8, 10 and 12 had unresectable disease

PR Partial response

SD Stable disease

PD Progressive disease

cT,cN Pretreatment clinical T,N staging

pT,pN Postoperative pathological T,N staging

na Not assessable

* Postchemoradiotherapy clinical staging by CT scan

had disease progression before the assessment schedule, so CT scan assessment was not done. Three patients with cT3-4 midrectal tumor were determined to be unresectable; two had progressive disease, the other one remained with unresectable cT4 tumor even when the enlarged locoregional lymph nodes had completely disappeared (cN0). They received further palliative chemotherapy.

Curative surgery was performed in nine patients (3 lower, 3 mid and 3 upper rectal cancer patients). One midrectal and all lower rectal cancer patients underwent abdomino-perineal resection (APR) with a permanent colostomy. The other midrectal cancer patients underwent low anterior resection (LAR) and the anal sphincters were preserved. Two upper rectal cancer patients underwent LAR. Hartman procedure was performed in the remaining patient.

The pretreatment staging, clinical response and pathological staging were compared and shown in Table 2. Three patients (25%) achieved pathological complete response. The pathological report of one patient revealed no residual viable tumor, even clinical partial response in the assessment before surgery as shown in Fig. 1. Pathological downstaging (from stage III to stage II or T2 to T0) occurred in 4 patients. One had stable disease and the other one had resectable

progressive disease (from stage II to stage III). No acute postoperative morbidity was noted. A midrectal cancer patient who had sphincter preservation had increased loose stool postoperatively.

All patients were regularly followed up following completion of the treatment. With a median follow up of 13 months, five patients had progressive or recurrent disease. Three of them developed distant metastases without local recurrence. The fourth patient developed local recurrence only. The last one who developed both local recurrence and distal metastasis expired 167 days after the treatment started. The recurrence-free durations of these five patients are 108 days, 122 days, 285 days, 735 days and 1,696 days, respectively. The patient with the longest recurrence-free duration initially had clinical stage II lower rectal cancer and was found to have lymph node metastasis after concurrent chemoradiotherapy and APR. She received postoperative chemotherapy for a total of 6 cycles (including preoperative chemotherapy). About 4 years after treatment, she developed adrenal, lung

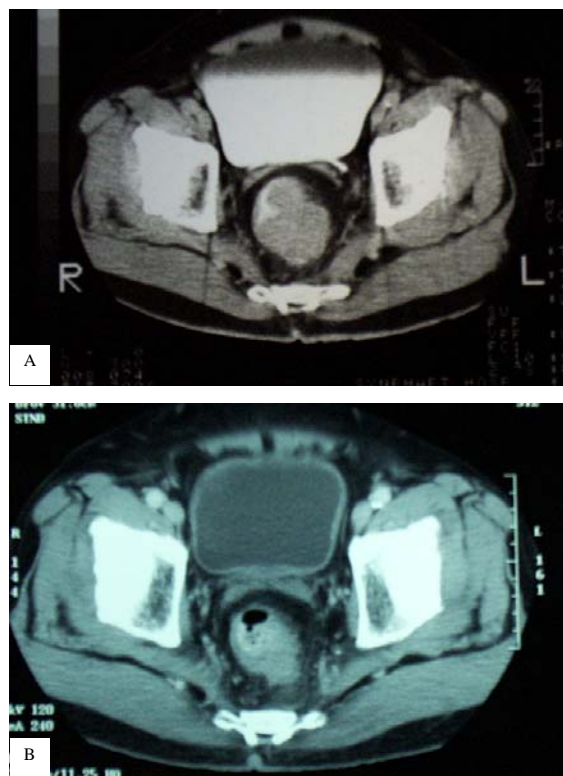


Fig. 1 Pelvic CT scan of a patient (no.5 in Table 2) A) before and B) after preoperative combined modality therapy. The tumor downstaging was demonstrated. This patient underwent LAR and the pathological complete response was reported

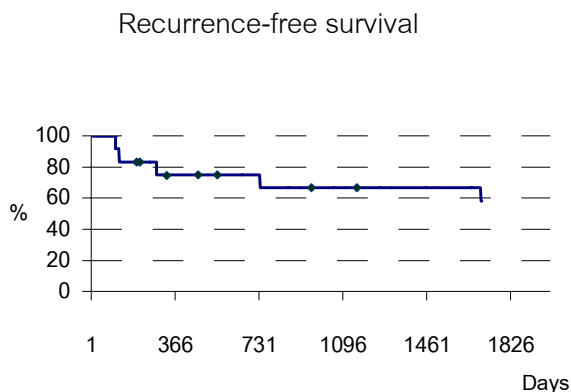


Fig. 2 Kaplan-Meier curve of recurrence-free survival: Five patients already developed recurrent disease. The 1-year recurrence free survival was 75%. The median follow-up time was 398 days

and lymph nodes metastases. The palliative chemotherapy was started. She has been alive with recurrent disease for 6 months. One patient developed second primary breast cancer at 1.5 years after the completion of postoperative chemotherapy. The one-year recurrence-free survival was 75% as shown in Fig. 2. However, the median recurrence-free survival and overall survival of the present study have not been reached.

Discussion

The authors reported a retrospective study of the preoperative chemoradiotherapy in the treatment of locally advanced rectal cancer patients performed between August 1998 and October 2003 at Ramathibodi Hospital.

According to NCCN (National Comprehensive Cancer Network) guidelines 2002, rectal cancer patients with lymph node-negative and T3 or T4 lesions or any lymph node-positive should receive adjuvant radiotherapy and chemotherapy, either pre- or postoperatively⁽¹⁶⁾. The potential advantages of the preoperative therapy include pathological downstaging^(17,18), less acute toxicity⁽¹⁹⁾, increased radiosensitivity due to more oxygenated cells⁽²⁰⁾ and enhanced sphincter preservation^(5,18,21).

Despite the paucity of phase III randomized controlled trials comparing preoperative and postoperative combined modality therapy in locally advanced disease, the available up-to-date data elicit some benefits from the preoperative approach. In the National Surgical Adjuvant Breast and Bowel project (NSABP) protocol R-03^(5,21), patients were randomized to receive either preoperative treatment or post-

operative treatment. The preoperative treatment included weekly 5-FU and leucovorin then concurrent 5-FU, leucovorin and 5,040 cGy radiotherapy then surgery and postoperative chemotherapy. The postoperative treatment included surgery and postoperative adjuvant treatment with the same regimen as preoperative treatment. Unfortunately, the present trial was unable to accrue as many patients as planned and closed early before the goal was met. Although the 1-year disease-free survival between both groups was not statistically different (83% preop vs 78% postop, $p = 0.29$), the present study demonstrated some benefits of preoperative over postoperative treatment with regards to sphincter preservation. More sphincter-sparing surgery could be performed in the preoperative versus postoperative group (50% vs 33%, respectively).

The largest prospective phase III randomized controlled trial comparing preoperative neoadjuvant and postoperative adjuvant combined modality therapy is the German trial (CAO/ARO/AIO-94) which enrolled as many as 805 patients since February 1995⁽²²⁾. In the neoadjuvant arm, the patients received 2 cycles of bolus 5-FU concurrently with radiotherapy preoperatively and 4 cycles postoperatively. In the postoperative arm, after surgery the patients received the first 2 cycles of bolus 5-FU concurrently with radiotherapy and 4 cycles after radiotherapy. Leucovorin was omitted from the chemotherapy regimen. As of now, the survival data has never been reported. However, the toxicity profiles between preoperative and postoperative groups were not different.

Another ongoing trial is comparing preoperative combined-modality therapy and preoperative radiotherapy alone in T3-T4 M0 resectable rectal cancer patients⁽³⁾. Two 5-day cycles of 5-FU 350 mg/m²/day and leucovorin (LV) 20 mg/m²/day were given in preoperative combined-modality arm. Only toxicities data was reported. Grade ≥ 2 acute diarrhea occurred more in the preoperative combined-modality arm (34.3%) than in the preoperative radiotherapy arm (17.3%) ($p < 0.005$). As of now, neither preoperative nor postoperative combined-modality therapy has been proved to be superior in terms of survival benefit.

Compared with the previous studies, the present study elicited similar results. The present pathological complete response (pCR) rate was 25% while the pCR rate of other trials varied between 8-24%^(4-7,9,14,15,17). However, the response rate did not correlate well with the survival. The 1-year recurrence-free survival was 75%. The local failure rate was 16.7%.

One patient with cT4 disease could undergo curative surgery and pathological tumor downstaging was reported. Unfortunately, such treatment could not be performed in the remaining two patients with pre-treatment unresectable cT4 disease. Sphincter-sparing surgery could be performed in 41.7%. However, the quality of the preserved sphincter is of concern, as one patient still has had frequent loose stools since the operation. The median bowel frequency per week was significantly more (20 vs 10) in the patients who underwent preoperative high-dose radiotherapy than surgery alone⁽²³⁾. Sphincter-sparing surgery could not be performed in all lower rectal cancer patients. As shown in another study, the possibility for sphincter saving depended on degree of response and the distance of the tumor from the anal verge⁽²⁴⁾.

Conclusion

The preoperative combined-modality therapy in locally advanced rectal cancer in Ramathibodi Hospital has demonstrated comparable response rate, toxicity and recurrence-free survival to other larger trials. As shown in many clinical trials, this method is an effective treatment option for patients who deny permanent colostomy.

Reference

1. Wolmark N, Wieand H, Hayams D, et al. Randomized trial of postoperative adjuvant chemotherapy with or without radiotherapy for rectal cancer NSABP R-02. *J Natl Cancer Inst* 2000; 92: 388-96.
2. Swedish Rectal Cancer Trial. Improved Survival with Preoperative Radiotherapy in Resectable Rectal Cancer. *N Engl J Med* 1997; 336: 980-7.
3. Bosset J, Calais G, Daban A, et al. Preoperative chemoradiotherapy versus preoperative radiotherapy in rectal cancer patients: assessment of acute toxicity and treatment compliance. Report of the 22921 randomised trial conducted by the EORTC Radiotherapy Group. *Eur J Cancer* 2004; 40: 219-24.
4. Bozzetti F, Andreola S, Baratti D, et al. Preoperative chemoradiation in patients with resectable rectal cancer: results on tumor response. *Annals of Surgical Oncology* 2002; 9: 444-9.
5. Hyams D, Mamounas E, Petrelli N, et al. A Clinical Trial to Evaluate the Worth of Preoperative Multimodality Therapy in Patients with Operable Carcinoma of the Rectum A Progress Report of National Surgical Adjuvant Breast and Bowel Project Protocol R-03. *Diseases of the Colon & Rectum* 1997; 40: 131-9.
6. Medich D, McGinty J, Parda D, et al. Preoperative chemoradiotherapy and radical surgery for locally advanced distal rectal adenocarcinoma: pathologic

findings and clinical implications. *Diseases of the Colon & Rectum* 2001; 44: 1123-8.

7. Minsky BD, Cohen AM, Enker WE, et al. Preoperative 5-FU, low-dose leucovorin, and radiation therapy for locally advanced and unresectable rectal cancer. *Int J Radiat Oncol Biol Phys* 1997; 37: 289-95.
8. Onaitis MW, Noone RB, Fields R, et al. Complete response to neoadjuvant chemoradiation for rectal cancer does not influence survival. *Ann Surg Oncol* 2001; 8: 801-6.
9. Onaitis MW, Noone RB, Hartwig M, et al. Neoadjuvant chemoradiation for rectal cancer: analysis of clinical outcomes from a 13-year institutional experience. *Ann Surg* 2001; 233: 778-85.
10. Sauer R, Fietkau R, Wittekind C, et al. Adjuvant versus neoadjuvant radiochemotherapy for locally advanced rectal cancer. A progress report of a phase-III randomized trial (protocol CAO/ARO/AIO-94). *Strahlentherapie und Onkologie* 2001; 177: 173-81.
11. Schaffer M, Thoma M, Wilkowski R, Schaffer P, Duhmke E. Radio-chemotherapy as a preoperative treatment for advanced rectal cancer. Evaluation of down-staging and morbidity. *Onkologie* 2002; 25: 352-6.
12. Schell S, Zlotecki R, Mendenhall W, Marsh R, Vauthey J, Copeland Er. Transanal excision of locally advanced rectal cancers downstaged using neoadjuvant chemoradiotherapy. *Journal of the American College of Surgeons* 2002; 194: 584-90.
13. Smith DE, Muff NS, Shetabi H. Combined preoperative neoadjuvant radiotherapy and chemotherapy for anal and rectal cancer. *Am J Surg* 1986; 151: 577-80.
14. Theodoropoulos G, Wise W, Padmanabhan A, et al. T-level downstaging and complete pathologic response after preoperative chemoradiation for advanced rectal cancer result in decreased recurrence and improved disease-free survival. *Diseases of the Colon & Rectum* 2002; 45: 895-903.
15. Tjandra J, Reading D, McLachlan S, et al. Phase II clinical trial of preoperative combined chemoradiation for T3 and T4 resectable rectal cancer: preliminary results. *Diseases of the Colon & Rectum* 2001; 44: 1113-22.
16. NCCN Rectal Cancer Panel Members. Rectal Cancer. *NCCN Practice Guidelines in Oncology*. 3 ed, 2003.
17. Hiotis S, Weber S, Cohen A, et al. Assessing the predictive value of clinical complete response to neoadjuvant therapy for rectal cancer: an analysis of 488 patients. *Journal of the American College of Surgeons* 2002; 194: 131-5.
18. Francois Y, Nemoz C, Baulieux J, et al. Influence of the Interval Between Preoperative Radiation Therapy and Surgery on Downstaging and on the Rate of Sphincter-Sparing Surgery for Rectal Cancer: The Lyon R90-01 Randomized Trial. *Journal of Clinical Oncology* 1999; 17: 2396-402.

19. Minsky B, Cohen A, Kemeny N, et al. Combined modality therapy of rectal cancer: decreased acute toxicity with the preoperative approach. *Journal of Clinical Oncology* 1992; 10: 1218-24.
20. Skibber J, Hoff P, Minsky B. Cancer of the rectum. In: Devita VT HS, Rosenberg SA, ed. *Cancer Principles & Practice of Oncology*. 6th ed. Philadelphia: Lippincott Williams & Wilkins, 2001: 1271-318.
21. Roh M, Petrelli N, Wieand S, et al. Phase III Randomized Trial of Preoperative Versus Postoperative Multimodality Therapy in Patients with Carcinoma of the Rectum (NSABP R-03). *Proc ASCO* 2001.
22. Sauer R, Fietkau R, Wittekind C, et al. Adjuvant vs neoadjuvant radiochemotherapy for locally advanced rectal cancer: the German trial CAO/ARO/AIO-94. *Colorectal Dis* 2003; 5: 406-15.
23. Dahlberg M, Glimelius B, Graf W, Pahlman L. Preoperative irradiation affects functional results after surgery for rectal cancer: results from a randomized study. *Dis Colon Rectum* 1998; 41: 543-9; discussion 549-51.
24. Minsky BD, Haller DG, Skibber JM. Multidisciplinary Management of Primary Colorectal Cancer. In: Perry MC, ed. *American Society of Clinical Oncology Thirty-Eight Annual Meeting*. Orlando, FL: American Society of Clinical Oncology, 2002: 471-7.

**การรักษาโรคมะเร็งลำไส้ใหญ่ตอนปลายระยะลุกลามไปอวัยวะหรือต่อมน้ำเหลืองข้างเคียงด้วยเคมีบำบัด
พร้อมกับรังสีรักษาก่อนการผ่าตัด: ประสิทธิภาพการรักษาใน ร.พ. รามาธิบดี**

เอกภพ สิริชัยนันท์, คณิต สัมบุญณานนท์, สมใจ แดงประเสริฐ, เรวดี พันธุ์เขียว, ธิติยา สิริสิงห, มณฑนา ณะไชย, วิรัช ไพรัชเวช, พวงทอง ไกรพิบูลย์, วรชัย รัตนธรราร

รายงานการรักษาผู้ป่วยโรคมะเร็งลำไส้ใหญ่ตอนปลายระยะ *locally advanced* 12 ราย ด้วยเคมีบำบัดพร้อมกับรังสีรักษาก่อนการผ่าตัดใน ร.พ. รามาธิบดี รอยโรคอยู่ที่ลำไส้ใหญ่ตอนปลายส่วนบน กลางและล่าง ร้อยละ 25, 50 และ 25 ตามลำดับ ผู้ป่วย 11 รายอยู่ในระยะที่ สาม อีก 1 รายอยู่ในระยะที่สอง ผู้ป่วยทุกรายได้รับยา 5-FU พร้อมกับรังสีรักษาตามด้วยการผ่าตัด (ถ้าผ่าตัดได้) ตามด้วยยาเคมีบำบัด ผลข้างเคียงที่พบบ่อยที่สุด คือ ท้องเสียระดับที่ 1-2 (ร้อยละ 58.3) ผู้ป่วย 5 ราย (ร้อยละ 41.7) ได้รับการผ่าตัด *sphincter-sparing surgery* ผู้ป่วยอีก 4 รายได้รับการผ่าตัด APR ในผู้ป่วยทั้งหมดที่ได้รับการผ่าตัด มี 3 ราย (ร้อยละ 25) ที่ไม่พบมะเร็งเหลือในรอยโรค ผู้ป่วยอีก 4 ราย (ร้อยละ 33.3) มีรอยโรคลดลง ผู้ป่วย 3 รายมีรอยโรคที่ไม่สามารถผ่าตัดได้ หลังการรักษาสิ้นสุด ผู้ป่วย 5 รายเกิดโรคกำเริบและเสียชีวิต 1 ราย อัตราการกำเริบที่รอยโรคเดิมเท่ากับร้อยละ 16.7 อัตราการอยู่รอดโดยไม่มีโรคกำเริบที่ 1 ปีเท่ากับร้อยละ 75 สรุปการรักษาผู้ป่วยโรคมะเร็งลำไส้ใหญ่ตอนปลายระยะ *locally advanced* ด้วยเคมีบำบัดพร้อมกับรังสีรักษาก่อนการผ่าตัดเป็นการรักษาที่มีประสิทธิภาพดี