

# Balloon Expandable Stents for Coarctation of the Aorta: Current Status and Technical Considerations: Case Report

Kritvikrom Durongpisitkul, MD\*, Duangmanee Laohaprasitiporn, MD\*,  
Prakul Chanthong, MD\*\*, Pradit Panchavinnin, MD\*\*\*

\* Department of Pediatrics, Faculty of Medicine, Siriraj Hospital, Mahidol University

\*\* Her Majesty Cardiac Center, Faculty of Medicine Siriraj Hospital, Mahidol University

\*\*\* Department of Internal Medicine, Faculty of Medicine Siriraj Hospital, Mahidol University

**Background:** Balloon expandable stents have been used to manage coarctation of the aorta (Co) in selected patients with very encouraging results.

**Material and Method:** The authors report here the first group of patients with Co who underwent a successful implantation of the new Palmaz Genesis™ stent with intermediate term follow up.

**Results:** There were 5 patients with an age range from 14 to 23 years old. All of them had significant Co and were receiving multiple anti-hypertensive medications. Primary stenting was performed in all patients. All of them had an immediate relief of the gradient. All antihypertensive medications were discontinued immediately in 4 patients. All patients had one year follow up which revealed a minimum gradient. One patient continues to receive oral antihypertensive medication.

**Conclusion:** In patients with coarctation of the aorta (native or recoarctation of aorta), stent implantation may be a feasible and improved option to relieve the stenosis. Short and mid term followup of these patients have shown encouraging results.

**Keywords:** Coarctation of aorta, angioplasty, stent, balloon dilatation

*J Med Assoc Thai* 2005; 88(2): 269-74

**Full text. e-Journal:** <http://www.medassochai.org/journal>

Balloon dilation has gained acceptance in the treatment of both native and recurrent coarctation of the aorta (Co)<sup>(1-5)</sup>. However, a number of patients develop recoarctation after balloon angioplasty<sup>(6,7)</sup> possibly as a result of elastic recoil or long segment stenosis. In order to overcome this problem, oversizing of the balloon size was undertaken in the past with a potential for complications such as acute dissection or late aneurismal dilatation. Intravascular stents provide radial strength to avoid recoil of the vessel, and a framework for endothelial growth<sup>(8)</sup>. Over the last few years stents have been used in selected patients to treat coarctation of the aorta both native and recurrent with encouraging results<sup>(9-12)</sup>. The authors report here the first group of patients who

underwent primary stenting for treatment of (Co) with one year follow-up.

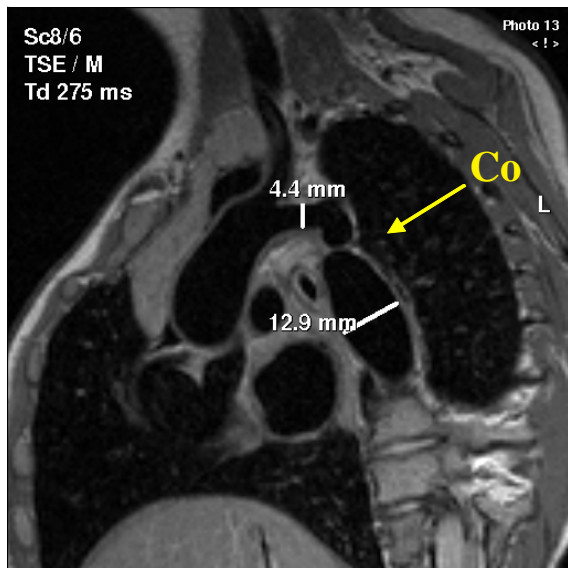
## Patients and Method

Patients who reached their adult size with a significant coarctation of the aorta were enrolled for the procedure. The coarctation of the aorta was evaluated by cardiac magnetic resonance imaging (MRI) to delineate the anatomy surrounding the stenotic area and aortic arch branching (Fig. 1). There were five patients who had a significant stenosis showing gradient across coarctation of the aorta more than 30 mmHg at rest with evidence of systemic hypertension and left ventricular hypertrophy. All 4 patients required multiple anti-hypertensive medications before the procedure.

## Cardiac catheterization procedures

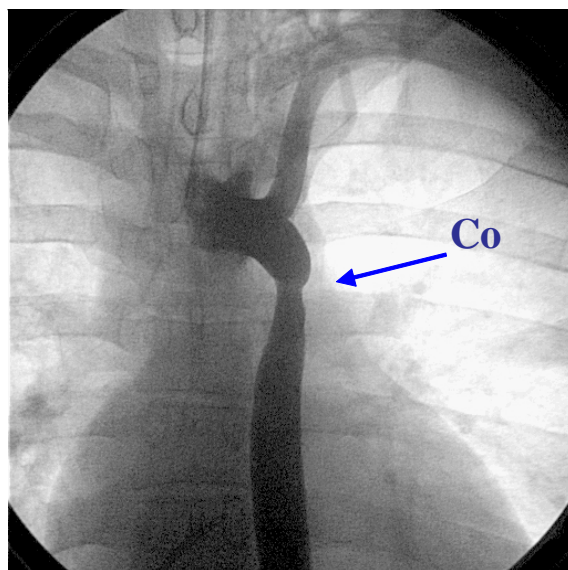
A detailed description of the transcatheter closure technique has been given previously<sup>(9-13)</sup>. In summary, the patients were intubated and placed

Correspondence to : Durongpisitkul K, Division of Pediatric Cardiology, Department of Pediatrics, Faculty of Medicine, Siriraj Hospital, Mahidol University, Bangkok 10700, Thailand. Phone: 0-2419-7000 ext. 5934, 5960-2, Fax: 0-2411-3010, E-mail: sikdr@mahidol.ac.th



**Fig. 1** Sagittal view of Cardiac Magnetic Resonance Imaging study of patient with coarctation of aorta. Co is coarctation site. Anterior and Posterior shelves were noted

under general anesthesia. A complete hemodynamic evaluation was performed. A withdrawal pressure gradient was obtained across the coarctation site. A 5F pigtail with a 20 mm marker band (Cook Medical Corp, Blomington, IN, USA) was positioned above the stenotic site to allow accurate calibration of the angiographic image. An aortogram was done in anteroposterior and lateral projections (Fig. 2). An end hole catheter was advanced across the coarctation



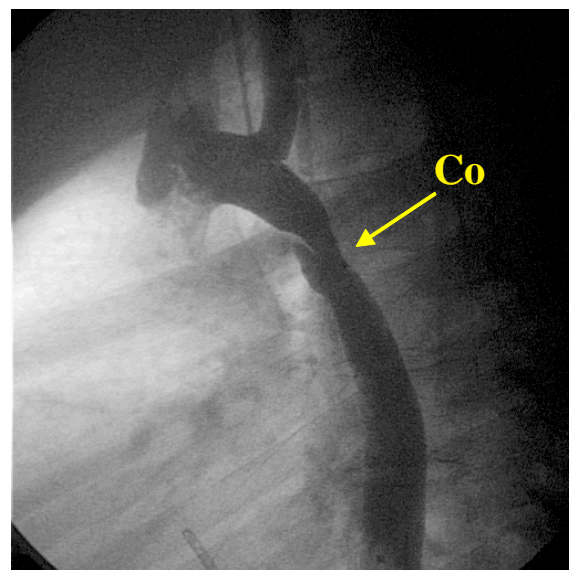
**Fig. 2A** Angiogram (anterior view) showed coarctation segment (Co)

site and a 0.035 inch Amplatz superstiff guidewire (Meditech, Boston, USA) was placed either in the ascending aorta or in a left subclavian artery. Then the catheter was exchanged for the long 11F Mullin Sheath (Cook Medical Comp, Blomington, IN, USA).

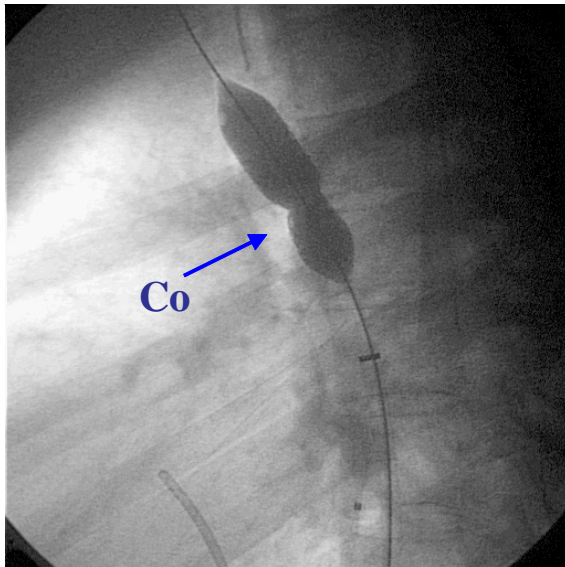
The size of the balloon catheter (Z Med II, Numed, Ontario, Canada) was selected to have a diameter approximating no more than 90% of the diameter of the descending aorta at the diaphragm. This diameter should also not be more than twice the size of the stenotic area. The balloon length was selected to be 4 cm. The specially designed stents (Palmaz-Genesis™ stent, Cordis/Johnson and Johnson) were crimped by hand to the balloon and advanced inside the Mullin sheath. The balloon was inflated up to the manufacturer's recommended burst pressure with a controlled pressure inflation device (Fig. 3). Pressure was sustained for up to 30 seconds. The gradient across the stent was remeasured and the aortogram was repeated (Fig. 4).

#### *Follow-up studies for patients who had primary stenting*

A chest radiograph and transthoracic color Doppler echocardiographic study were performed on all the patients 24 hours after the procedure. Each patient took an anti-platelet dose of aspirin for up to six months. The patients were scheduled for chest radiograph to compare the position of the device one week after the procedure. Repeat visits for each patient



**Fig. 2B** Angiogram (sagittal view) showed coarctation segment (Co). Anterior shelf was also noted



**Fig. 3** Angiogram (sagittal view) showed a fully dilated balloon with fully expanded stent. A small constriction at the coarctation area (Co) was also noted

were done at one month, three months, six months and one year. Echocardiogram was performed to identify any residual shunt or possible device malposition.

### Results

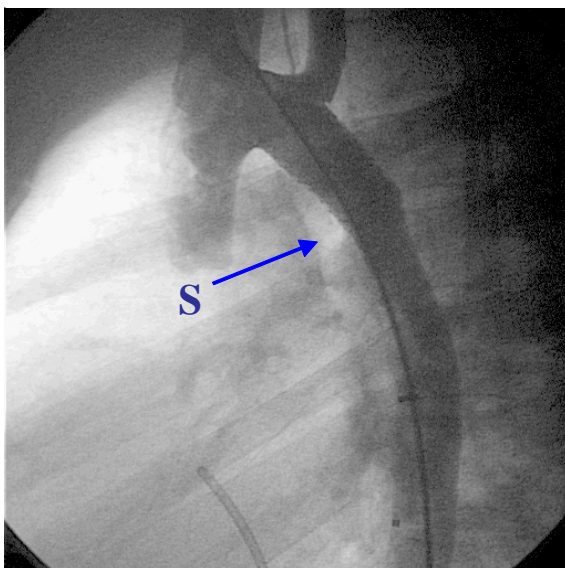
There were 5 patients who had successful primary stenting of the coarctation of aorta performed. Their ages were 15 years old (y/o) boy, 22 y/o woman,

14 y/o boy, 17 y/o girl and 22 y/o woman. Their primary lesion were native coarctation of aorta in four patients and recurrent coarctation of aorta after repair of the interrupted aortic arch in one patient. The results of cardiac catheterizations performed are shown in Table 1.

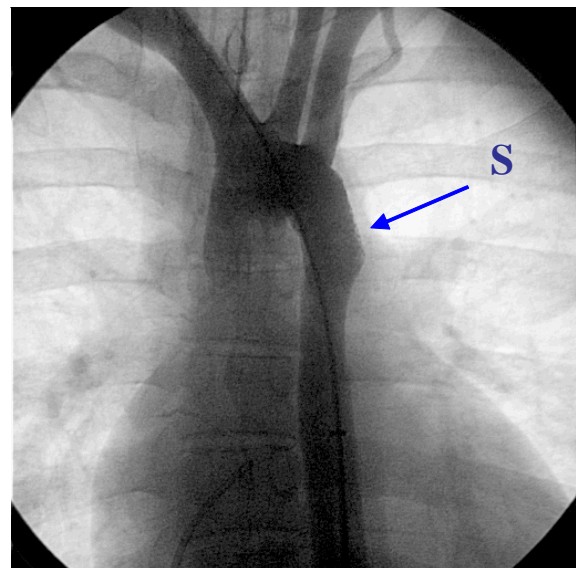
All patients underwent successful dilatation and stenting coarctation segment without complication. All of them were dismissed on the 2<sup>nd</sup> day post procedure except one patient who developed swelling of the right groin which was found to be an arteriovenous fistula at the puncture side (right groin) after the 3<sup>rd</sup> day during the hospitalization. He subsequently underwent a repair of the arteriovenous fistula and stayed another 10 days in the hospital. All patients received aspirin (81 mg) for 6 months. All anti-hypertensive medications were discontinued immediately in 4 patients. At the end of one year follow-up only one out of five patients required oral medication for anti hypertension treatment due to abnormal blood pressure (Table 2).

### Discussion

Coarctation of the aorta, if left untreated subsequently can create a significant health risk. Up to 90% of the patients with isolated coarctation of aorta may die before the age of fifty of complications which included aortic rupture, intracranial hemorrhages, severe hypertension, endocarditis or heart failure<sup>(14,15)</sup>. Relief of the obstruction of the coarctation site have



**Fig. 4A** Angiogram (sagittal view) showed successful dilatation of the coarctation site with stent implanted



**Fig. 4B** Angiogram (frontal view) showed stent placement (S) over wire in the aorta

**Table 1.** Showing demographic data in all four patients

	Patients	Pre BP (mmHg)	weight	Pre gradient (mmHg)	Pre diameter (mm)	Post gradient (mmHg)	Post diameter (mm)
I	18 y/o boy	190/70	83 kg	30	7	< 5	18
II	19 y/o girl	150/90	61 kg	59	8	< 5	15
III	15 y/o boy	160/100	48 kg	50	6	< 5	14
IV	17 y/o girl	170/100	40 kg	50	6	< 5	15
V	22 y/o girl	160/90	45 kg	45	6	< 5	14

y/o = years old, Pre BP = Pre dilatation blood pressure, Pre-gradient = Pre dilatation gradient across coarctation, Pre diameter = Pre dilatation diameter at coarctation site, Post gradient = post dilatation gradient across coarctation, Post diameter = Post dilatation diameter at coarctation site

**Table 2.** Showed follow up data on patients at one month (1 Mo.), 6 months (6 Mo.) and 1 year (1 yr)

Patients	1 Mo. BP (mmHg)	1 Mo. P (mmHg)	6 Mo. BP (mmHg)	6 Mo. P (mmHg)	1 yr BP (mmHg)	1 yr P (mmHg)
I*	135/63	< 5	150/90	< 10	150/90	< 10
II	140/70	< 5	135/70	< 5	120/70	< 5
III	145/63	< 10	145/65	< 5	140/60	< 5
IV	159/94	< 10	134/70	< 5	136/85	< 5
V	160/70	< 10	140/70	< 5	130/70	< 5

BP = blood pressure, P = gradient across coarctation of aorta obtained by echocardiogram

\*one patient require beta blocker at the end of one year

improved the long-term survival of these patients. The major decisions of the cardiologist is to choose the right approach for the specific patient, whether surgery, balloon or stent. The patient's age and weight with a history of surgery influences a great deal the management strategy. The use of stents to treat coarctation of the aorta has been dated to the mid 1980s<sup>(16)</sup> both native and post operative<sup>(17,18)</sup>.

#### Old and new stents

The most commonly used stent for coarctation of the aorta in the past was the large Palmaz stents (P308 from Johnson & Johnson Interventional Systems Co., Warren, NJ, USA). These stents have a recommended expanded diameter between 8-12 mm but are commonly over dilated to 18-20 mm with some difficulty. A significant number of patients have had P308 stents implanted in the coarctation site with excellent results<sup>(9-12)</sup>. Limitations of existing stents were recognized. However, over dilation of these stents results in significant foreshortening < 33% at 12 mm and up to 50% at 18 mm<sup>(11)</sup> and is met with significant resistance. Desirable characteristics in the implantable stents would include flexibility, relatively small profile to allow introduction in children or small adults, ability to further dilate to adult size as the patient grows, high

radial strength, non sharp edges, less foreshortening after oversizing. Significant improvement in the existing stent designs as well as introduction of new stents has been accomplished in the recent years. The Palmaz-Genesis<sup>TM</sup> stent (Cordis/Johnson and Johnson) was introduced to overcome some of the short falls of the Palmaz stents. The authors reported here the first five patients who had coarctation of the aorta and stenting by the Palmaz-Genesis<sup>TM</sup> stents.

Generally, excellent results have been achieved with clinical effectiveness of primary stenting of coarctation of the aorta as judged by almost complete abolishment of the gradient in > 95% in all five patients. Restenosis does not appear to be a major problem during follow up and in a number of patients further dilatation has been effective for residual stenosis<sup>(9-13)</sup>. Stents also appear to effectively treat severe complex coarctations with hypoplasia of the isthmus and transverse arch and long tubular stenosis. In adults, surgical repair is also challenging and will often necessitate the use of aorto-aorto bypass. Despite the obvious trauma induced to the aortic wall, major complications appear to be rare. Reports on dead are rare, with a need for emergency surgery in less than 1% of cases<sup>(8,19)</sup>. Intravascular stents can maintain the patency of a stenotic lesion by eliminating the elastic

recoil of the tissue and can extend over a relatively long segment of stenosis, thus decreasing the need for over expansion or causing intimal tear in these vessels<sup>(8)</sup>.

### Conclusion

The short term results of the transcatheter treatment of aortic coarctation appear excellent. The use of endovascular stents appears to be relatively safe and highly effective when compared to the operative risk. At one year follow-up almost all the patients maintained normal blood pressure. In selected patients with coarctation of the aorta (native or recoarctation of aorta), stent implantation may be a feasible and improved option to relieve the stenosis. Short and mid term followup of these patients have shown encouraging results.

### References

1. Anjos R, Quershi SA, Rosenthal E, Murdoch I, Hayes A, Parsons J, Baker EJ, Tynan M. Determinants of hemodynamic results of balloon dilation of aortic recoarctation *Am J Cardiol* 1992; 69: 665-71.
2. Kan JS, Whilte RI, Mitchell SE, Farmlett EJ, Donahoo JS, Gardner TJ. Treatment of restenosis of coarctation by percutaneous transluminal angioplasty. *Circulation* 1983; 68: 1087-94.
3. Lock JE, Keane JF, Fellows KE. The use of catheter intervention procedures for congenital heart disease. *J Am Coll Cardiol* 1986; 7: 1420-3.
4. Rao PS, Wilson AD, Chopra PS. Immediate and follow-up results of balloon angioplasty of postoperative recoarctation in infants and children. *Am Heart J* 1990; 120: 1315-20.
5. Rao PS. Balloon angioplasty of aortic coarctation: A review. *Clin Cardiol* 1989; 12: 618-28.
6. Mendelsohn AM, Lloyd TR, Crowley DC, Sandhu SK, Kocis KC, Beekman RH. Late follow-up of balloon angioplasty in children with a native coarctation of the aorta. *Am J Cardiol* 1994; 74: 696-700.
7. Rao PS, Galal O, Smith PA, Wilson A. Five to nine year follow-up results of balloon angioplasty of native coarctation in infants and children. *J Am Coll Cardiol* 1996; 27: 462-70.
8. Ovaert C, Benson LN, Nykanene D, Freedom RM. Transcatheter treatment of coarctation of the aorta: a review. *Pediatr Cardiol* 1998; 19: 27-44.
9. Bulbul ZR, Bruckheimer E, Love JC, Fahey JT, Hellenbrand WE. Implantation of balloon-expandable stents for coarctation of the aorta: implantation data and shortterm results. *Cathet Cardiovasc Diagn* 1996; 39: 36-42.
10. Ebeid MR, Prieto LP, Latson LA. The use of balloon expandable stents incoarctation of the aorta: short and intermediate term follow up. *J Am Coll Cardiol* 1997; 30: 1847-52.
11. Hamadan MA, Maheshwari S, Fahey JT, Hellenbrand WE. Endovascular stents for coarctation of the aorta: initial results and intermediate-term follow-up. *J Am Coll Cardiol* 2001; 38: 1518-23.
12. Cheatham JP: Stenting of coarctation of the aorta. *Catheter Cardiovasc interv* 2001; 54: 112-25.
13. de Lezo JS, Pan M, Romero M, Medina A, Segura J, Lafuente M, Pavlovic D, Hernandez E, Melian F, Espada J. Immediate and follow-up findings after stent treatment for severe coarctation of the aorta. *Am J Cardiol* 1999; 83: 400-406.
14. Campbell M. Natural history of coarctation of the aorta, *Br Heart J* 1970; 32: 633-40.
15. Kirklin JW, Barratt-Boyes BG. *Coarctation of the Aorta and Interrupted Aortic Arch*. Cardiac Surgery. New York: Churchill-Livingston, 1992: 1263-325.
16. Palmaz JC, Encarnacion CE, Garcia OJ, Schatz RA, Rivera FJ, Laborde JC, Dougherty SP. Aortic bifurcation stenosis: treatment with intravascular stents. *J Vasc Interv Radiol* 1991; 2: 319-23.
17. Mullins CE, O'Laughlin MP, Vick GW 3rd, Mayer DC, Myers TJ, Kearney DL, Schatz RA, Palmaz JC. Implantation of balloon-expandable intravascular grafts by catheterization in pulmonary arteries and systemic veins. *Circulation* 1988; 77: 188-99.
18. O'Laughlin MP, Slack MC, Grifka RG, Perry SB, Lock JE, Mullins CE. Implantation and intermediate-term follow-up of stents in congenital heart disease. *Circulation* 1993; 88: 605-14.
19. Hellenbrand WE, Allen HD, Golinko RJ, Hagler DJ, Lutin W, Kan J. Balloon angioplasty for aortic recoarctation: results of valvuloplasty and angioplasty of congenital anomalies registry. *Am J Cardiol* 1990; 65: 793-7.

---

## การขยายและใส่ขดลวดค้ำยันในผู้ป่วย coarctation of aorta

กฤตยวีกรม ดุรงค์พิศิษฏ์กุล, ดวงมณี เลหาประสิทธิ์พร, ประคัลภ์ จันทร์ทอง, ประดิษฐ์ ปัญจวิณิน

**วัตถุประสงค์:** รายงานการรักษาในกลุ่มผู้ป่วยโรคหัวใจพิการแต่กำเนิดชนิดที่มีการตีบแคบของเส้นเลือด aorta โดยใช้การขยายด้วยบอลลูน และใส่โครงขดลวดเป็นตัวค้ำยันแทนการผ่าตัด

**วัสดุและวิธีการ:** ได้คัดเลือกผู้ป่วย โดยผู้ป่วยมีความดันโลหิตสูงจากเส้นเลือด aorta ตีบแคบ และให้การรักษาโดยการขยายเส้นเลือดและใส่โครงขดลวด รวมทั้งได้ติดตามผู้ป่วยเป็นระยะเวลา 1 ปี

**ผลการศึกษา:** ผู้ป่วย 5 รายได้รับการขยายเส้นเลือด (อายุ 14 ถึง 23 ปี) ได้ผลดีโดยสามารถหยุดการให้ยาลดความดันโลหิตในผู้ป่วยทุกราย การติดตามการรักษาที่ระยะเวลา 1 ปี พบว่าผู้ป่วยทุกรายมีภาวะการอุดตันหลังหลอดเลือดที่ตีบแคบน้อยมาก

**สรุป:** สามารถใช้การขยายเส้นเลือดและใส่ขดลวดค้ำยันในผู้ป่วย coarctation of aorta ได้เป็นผลดี โดยสามารถหยุดยาลดความดันโลหิตในผู้ป่วยหลังหัตถการได้ทุกราย หลังการขยายเส้นเลือดและใส่โครงขดลวด

---