

Pediatric Cochlear Implantation: Experience in Thai Patients

Chanida Kanchanalarp, MD, FRCOT, FICS*,
Wichit Cheewaruangroj, MD, FRCOT*, Lalida Kasemsuwan, MD, FRCOT*,
Cheamchit Thawin, MA*, Siriparn Sriwanyong, MBA, MS*

* Department of Otolaryngology, Faculty of Medicine, Ramathibodi Hospital, Mahidol University

Objective: This study was to evaluate the result of cochlear implantation in Thai pediatric patients from 1999-2003.

Design: A prospective, open-labeled study.

Setting: University teaching hospital.

Material and Method: Long term surgical and audiology results comparison after cochlear implantation in 2 cases with Mondini anomaly, 7 normal cochlea cases and a case of post meningitis post lingual child.

Main outcome measures: Speech perception tests battery.

Results: Among 10 children, 8 were implanted with Nucleus 22/24; the other two were implanted with Med-el device system. The pre-operated cochlea in 2 cases showed Mondini deformity; both had gushers during the operation with a good outcome. The other 8 cases had normal cochlea although one was deaf from bacterial meningitis. There were 3 re-implantations. Speech production and perception was improved faster in the two children implanted with Med-el than those implanted with Nucleus devices.

Conclusion: Cochlear implantation in Mondini cases can be successful in speech production and perception. Speech perception ability depended on the age of implantation and preoperative rehabilitation.

Keywords: Mondini, Cochlear implant, Inner ear anomaly

J Med Assoc Thai 2005; 88(4): 484-91

Full text. e-Journal: <http://www.medassocthai.org/journal>

Multi-channel cochlear implantation was first performed in Thailand in 1994 at Chulalongkorn hospital, Chulalongkorn University⁽¹⁾ and second performed in Thailand in 1995 at Ramathibodi Hospital, Faculty of Medicine, Mahidol University⁽²⁾, Bangkok, Thailand. Cochlear implantation has long been the treatment of choice for acquired profound sensorineural deafness in adults and, more recently, young children. This technology has been applied in later childhood or in adulthood, after learning speech and oral language. In Ramathibodi Hospital, the school for Speech and Audiology does the preoperative and postoperative evaluations, resulting in satisfactory benefit in our cochlear implantation. The authors wished to evaluate the outcomes of cochlear implan-

tation in our deaf children after postoperative rehabilitation. The operative technique is detailed and the overall results will be discussed.

Material and Method

Between 1999 and 2003, 10 children with bilateral severe to profound hearing loss and no benefit from hearing aids use, received multi-channel cochlear implantation. There was one post meningitis deafness and 9 congenital prelingual deafness patients. The mean age was 4.9 years and a range of 2/12 years to 14 years. The types of device were as follows: Eight children were implanted with Nucleus devices, 3 of which were Nuc 22 channel, and 5 of which were Nuc 24 channel. The other 2 children had Med-El device combi 40+. There were 2 cases of Mondini deformity with intraoperative gushers.

There were 3 re-implantation of Nucleus devices because of wrong positioning in small

Correspondence to : Kanchanalarp C, Department of Otolaryngology, Faculty of Medicine, Ramathibodi Hospital, Mahidol University, Rama VI Rd, Bangkok 10400, Thailand. Phone: 0-2354-7275, Fax: 0-2354-7233, E-mail: niddk1@yahoo.com

children at 2 9/12, 3 5/12 and 3 7/12 years. The authors used intraoperative telemetry to confirm function of electrodes in 2 cases of small children aged 2 9/12 and 2 8/12 implanted with Med-El Combi 40+. The response was evaluated with speech perception tests battery at 3, 6 and 12 months.

Case Report: 2 cases of Mondini deformity

The first case of Mondini deformity:

A 14-year-old boy had congenital deafness with a family history of deafness in his cousin. He had hearing aids both ears fitted when he was 2 years old but there was no benefit from the hearing aids. He was enrolled in a special school for the deaf. His mother said that he had a head trauma at 4 months of age. The CT scan of the temporal bone showed inner ear malformation. Bilateral dilatation of the internal auditory canals with marked hypoplasia of the labyrinths were noticed. Dilated basal turn, large vestibule and malformation of the semicircular canals were also observed. The authors prepared connective tissue intraoperatively before cochleostomy. There was a strong gusher as the authors performed the cochleostomy with a small hole. The perilymphatic gusher was estimated about 20 ml. A cochlear device Nucleus 22 was easily placed in the hole and sealed with the prepared connective tissue. In addition to connective tissue, gelfoam was packed into the cochleostomy and the posterior tympanotomy. Postoperative bed rest and intravenous antibiotics were prescribed for 24 hours. No other complications, no dizziness, no facial weakness and no fluid leakage were observed. The patient stayed 3 days after operation in the hospital. After the patient received speech rehabilitation, he was mainstreamed to a normal school one year after the operation.

Second case of Mondini deformity:

A 4 6/12 years old girl had congenital prelingual deafness and a family history of bilateral deafness in her uncle. She had a history of normal delivery and hearing aids were fitted in both ears when she was 2 years old. Auditory brainstem response showed no response of wave V, tympanogram showed type A with no stapedial reflex. Computerized tomogram showed one and a half turns of the cochlea with no dilatation of the vestibular aqueduct. During the operation, the authors prepared connective tissue of the temporalis fascia before the cochleostomy. After the cochlea was drilled, cochleostomy fluid leakage was measured at about 5 ml. Then the array of Nucleus

22, was placed and the cochleostomy was sealed with tissue and gelfoam. No complication after surgery was observed. Three days of intravenous antibiotic postoperation was prescribed. Two years later postoperative CT of the temporal bone was evaluated. The device array was found in the cochlea about half of its length. The child developed communication skills after 2 years and was mainstreamed to normal school.

For these 2 operative cases, the authors did not have telemetry at that time. There were no complications of either case of Mondini deformity and both children were mainstreamed to normal schools.

Results

There were 9 congenital deafness children, 2 were inner ear abnormality with severe hearing loss and positive familial history and there were 2 perilymph leakages. The first and second cases exhibited good communication skills. They were mainstreamed to normal schools. The device in the first and second Mondini cases was a Nucleus 22 which had only partial insertion with no complication during operation. The authors had one postlingually deaf child with post meningitis hearing loss but no ossified cochlea. He received significant benefit from the cochlear implant, and had significant improvement in his speech perception ability 3, 6 and 12 months after implantation.

There were 4 cases of complication; 3 re-implantations of Nucleus 24 and one case of post-auricular abscess. The cause of failure was the wrong position of the Nucleus 22 and also at that time the authors did not use telemetry or fluoroscopy intraoperatively. After re-implantation of Nucleus 24, they developed a satisfactory result in communication and education. The case of post auricular abscess responded well to antibiotic, and there was no flap necrosis.

There were 2 perilymph leakages, one strong gusher and one minimal leakage. The authors did not do a lumbar puncture in these cases.

There were neither postoperative facial weakness, vertigo nor fever observed.

Speech and language rehabilitation

Test materials

The speech perception tests battery consisted of spondee words, picture identification test and children vocabulary test as shown in Table 1.

The speech perception tests in the present study consisted of 3 tests with 2 closed-set and one open-set.

Table 1. Details of speech perception tests battery, material and response format

Test	Material	Presentation	Response format
Spondee (RAMA SRT)	Spondee 12 items each presented 2 times	-live voice: A, V, AV*	-Closed-set: picture pointing 4 alternative
Ramathibodi Picture Identification Test	-Nouns- Monosyllables 6 lists 20 items per list	-live voice: A, V, AV	-Closed-set: picture pointing 6 alternative
Children Vocabulary Test**	- 1-2 word (Nouns)12 items	-live voice: A, V, AV	-Open-set: word repetition

* A = Auditory, V = Visual, AV = Auditory and Visual; ** Poonpit Amatayakul, 1969⁽⁷⁾

The percentage correct scores of spondee test in ten patients with a post operative rehabilitation period 3, 6, and 12 months are shown in Fig. 1. The results showed increased mean percentage correct

score when using auditory-visual condition.

The mean percentage correct of closed-set Picture Identification test in ten patients post rehabilitation period within 3, 6, 12 months is shown in Fig. 2.

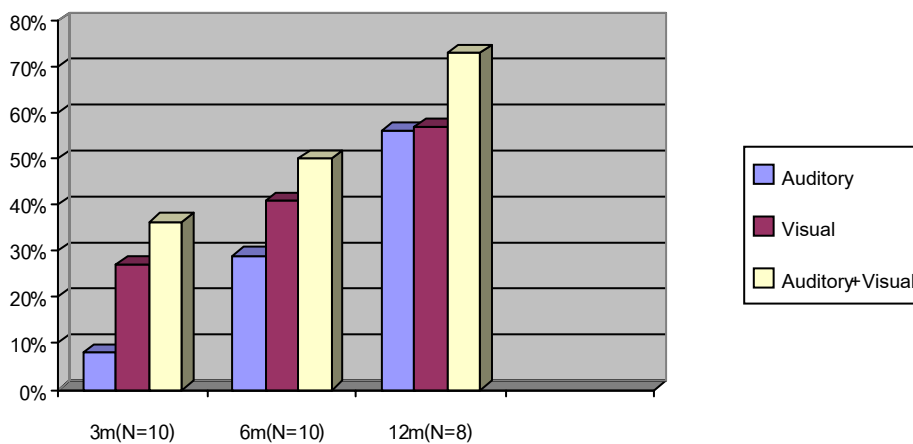


Fig. 1 Percentage correct score of closed-set spondee test within 3, 6, 12 months post aural rehabilitation (closed-set)

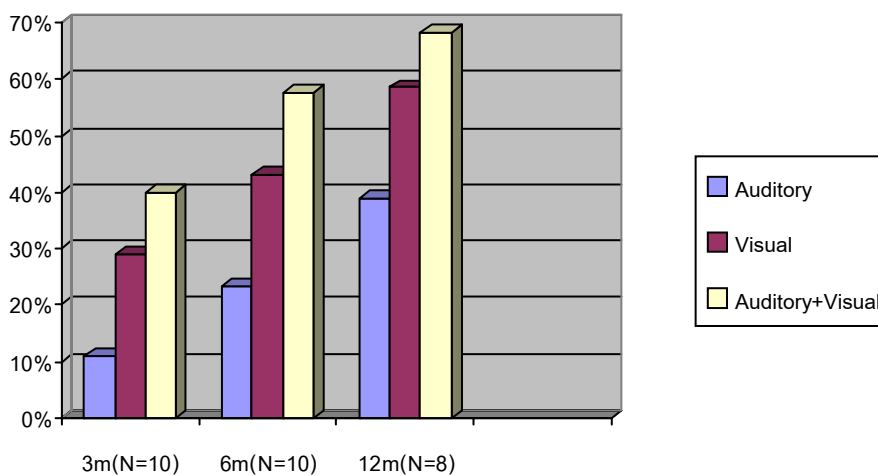


Fig. 2 Percentage correct score of closed-set Picture Identification Test with 3, 6, 12 months post aural rehabilitation (closed-set)

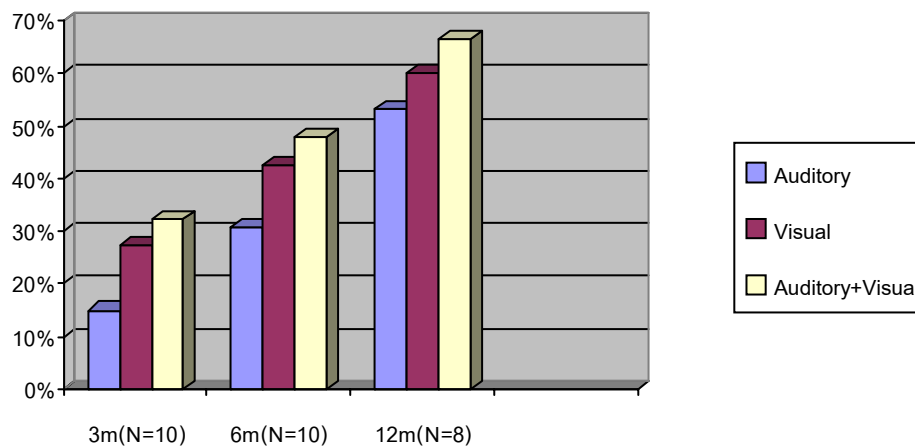


Fig. 3 Percentage correct score of open-set children vocabulary test within 3, 6 and 12 months post aural rehabilitation (open-set)

There was progressive improvement in the post operative rehabilitation period 3, 6 and 12 months respectively.

The mean percentage correct score of open-set children vocabulary test in ten patients in the post rehabilitation period within 3, 6, and 12 months is shown in Fig. 3. The vocabularies were relatively improved with increasing periods of time. The correct vocabulary score was also enhanced when using auditory-visual condition.

2 Mondini patients

Case I

A 14-year-old boy who underwent cochlear implantation (CI) surgery with 22-channel Nucleus device on the right ear. The rehabilitation program began 1 month after surgery. The speech perception ability was evaluated at 3, 6, and 12 months. The results are shown in Table 2.

Case II

A 4 year-6 month-old girl who underwent CI surgery with 24 channel Nucleus devices on the right

ear. The rehabilitation program began 1 month after surgery. The speech perception ability was elevated at 3, 6, and 12 months. The results are shown in Table 3.

Result of 2 patients with Med-el devices

Two Thai girls aged 2 9/12 and 2 8/12 years old underwent CI surgery with Med-el devices on the left and right ear, respectively. The rehabilitation program began 1 month after surgery. The speech perception ability was evaluated at 3 and 6 months. The results are shown in Fig. 4.

The results showed rapid improvement of speech reception ability in these two girls when compared with the speech reception ability in all 10 children as shown in Fig. 4. This advantage may be due to the age of implantation and the fact that both were good hearing aid users and both attended a rehabilitation program before surgery.

Discussion

The advantages of intraoperative fluoroscopy include the avoidance of complications such as extracochlear array displacement, intrameatal array

Table 2. The speech perception results in 14 years Mondini case after rehabilitation of 3, 6, and 12 months

Rehabilitation period (months)	Spondee test			Picture Identification			Vocabulary test		
	A	V	A+V	A	V	A+V	A	V	A+V
3	10	30	70	15	30	50	16.66	50.60	75.00
6	30	60	80	25	60	70	50.00	66.60	83.33
12	70	90	100	50	70	80	50.00	66.60	83.33

A = Auditory, V = Visual, A+V = Auditory + Visual

The results showed improvement in all speech perception battery tests. The correct score improved sequentially with rehabilitation period of 3-12 months. In addition the correct score was most improved in auditory + visual condition.

Table 3. The speech perceptions results in 4 and half years Mondini case after rehabilitation period of 3, 6, and 12 months

Rehabilitation period (months)	Spondee test			Picture Identification			Vocabulary test		
	A	V	A+V	A	V	A+V	A	V	A+V
3	10	30	60	10	20	40	16.66	41.66	75.00
6	30	40	70	20	30	50	25.00	33.00	75.00
12	40	60	80	30	60	70	50.00	50.00	75.00

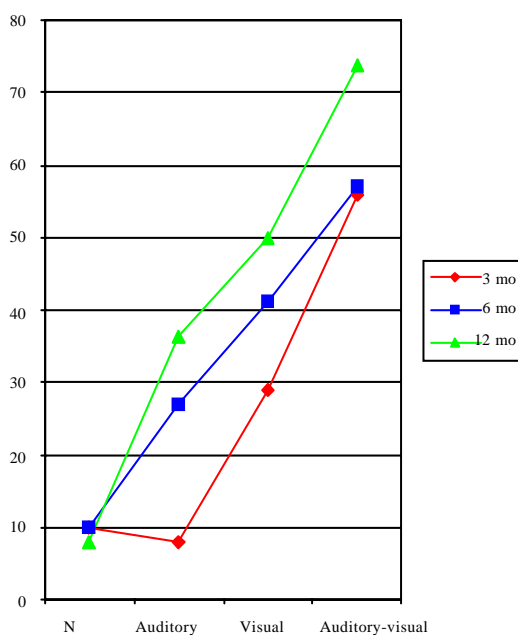
A = Auditory, V = Visual, A+V = Auditory + Visual

There were increased percentage correct score of speech perception test batteries. The improvement related to the period of rehabilitation and using auditory-visual condition.

insertion, and significant bending or kinking. Cochlear implantation with fluoroscopy is very important for the surgeons⁽³⁾. Fluoroscopy can be performed with minimum risk to the patient and operating staff if the outlined precautions are taken. It is indicated in cases where the intracochlear behavior of the electrode array cannot be predicted. A difficult condition was encountered when implanting new electrode designs such as cases with severely malformed inner ears, or cases of severe intraluminal obstruction requiring a double -array insertion. The authors experienced 3 re-implantations after the wrong position of devices and strongly suggest intraoperative fluoroscopy in every case where there is an abnormal cochlea.

One post meningitis hearing loss case with no ossified cochlea received significant benefit from CI⁽⁴⁾. The child was postlingually deaf at 2 years old, and he had CI at age 4 1/2 years old, he could continue his speech and rapidly developed his communication. The use of cochlear implantation to treat patients with inner ear malformations such as Mondini dysplasia has been increasingly successful⁽⁵⁾. In the present study, Mondini patients had a very good result when compared with the average score of speech perception in the group study. The perilymph gusher occurred in 2 cases, which were easily controlled by quickly inserting the electrode array and sealing the cochleos-tomy with tissue.

The mean score of closed -set of 10 children (Spondee test)



The mean percentage score of 2 Med-el patient (Spondee test)

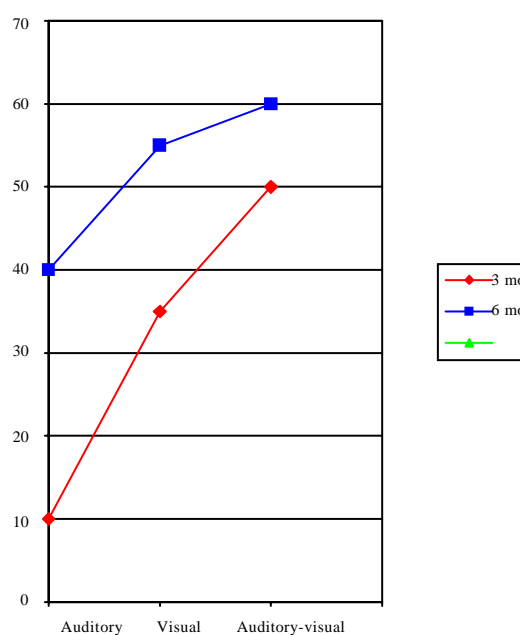
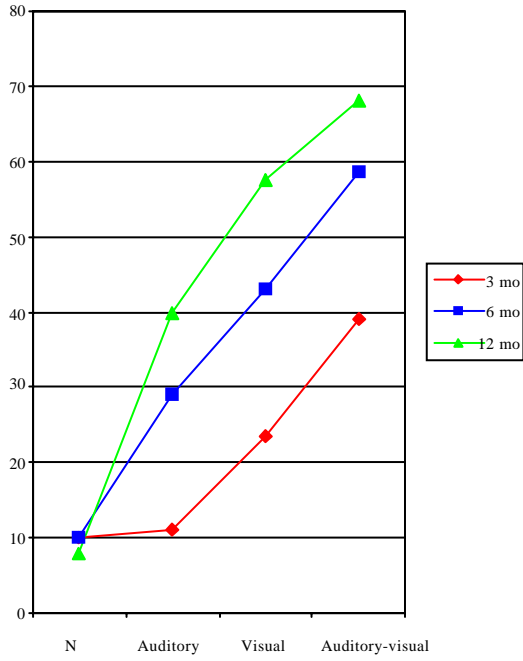
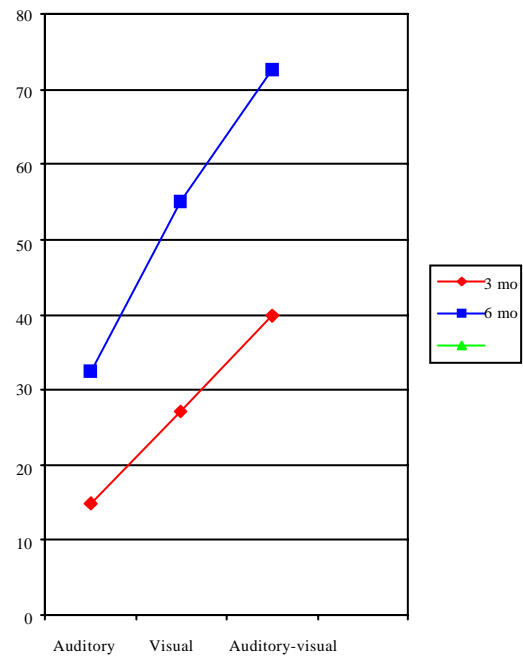


Fig. 4 Speech perception tests battery between 10 children and 2 Med-el patients

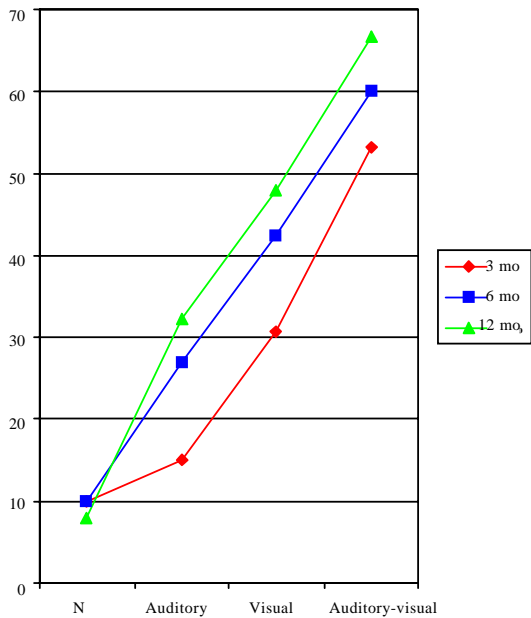
The mean percentage correction of 10 children
(Picture Identification test)



The mean percentage score of 2 Med-el patients
(Picture Identification test)



The mean percentage correct score of open-set in children
(vocabulary test)



The mean percentage score of 2 Med-el patients
(vocabulary test)

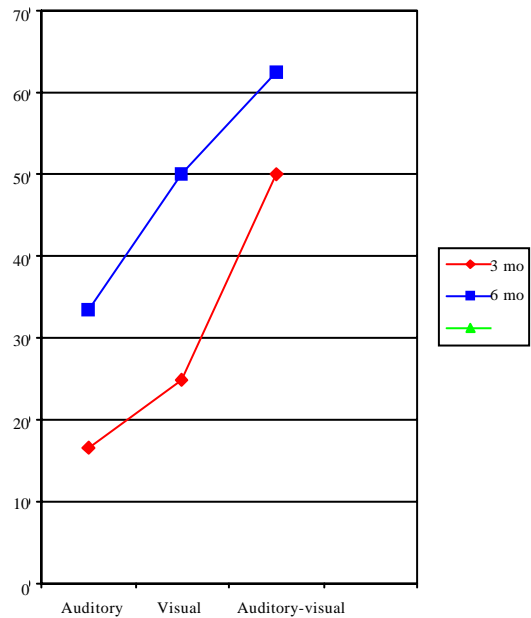


Fig. 4 Speech perception tests battery between 10 children and 2 Med-el patients

Cochlear implantation is recognized as a valuable intervention with important implications for the acquisition of speech perception and verbal language in children with severe to profound hearing impairment. Auditory rehabilitation, language intervention and close co-ordination between parents, schools and the implant center are necessary to maximize efficacy. Early identification of hearing aid use and language intervention and cochlear implantation by 2 years of age are positive predictors for language acquisition. Increased access to mainstream education and gains in quality of life are long term benefits that render cochlear implantation a cost-effective intervention⁽⁶⁾.

Conclusion

Surgical result: All of the 10 children who had cochlear implantation: 8 with Nucleus device and 2 with Med-el, had no complications, 2 gushers were stopped with tissue and gelform immediately after insertion of device array (22 Nucleus).

Audiologic result: Speech perception ability depended on the following factors:

1. Age at implantation
2. Speech and language rehabilitation before implantation
3. Communication mode: auditory combined with visual mode

In addition, there was no difference between the child with normal cochlea and the child with Mondini dysplasia in regard to speech perception ability.

All of the 10 children have improved speech perception ability after one year post CI especially auditory combined with visual mode.

Also, speech production and perception was improved faster in the two children implanted with Med-el devices.

Acknowledgements

The authors wish to thank the following persons who acted as their teachers during their

traineeship under their supervision: Prof. Dr. Graham Clark (Australia), Prof. Dr. Helms and Prof. Dr. Joachim Mueller (Germany), and we also wish to thank the following people who significantly contributed their assistance to this project: Prof. Dr. Andrew van Hasselt (Hong Kong), Prof. Dr. Rudolf Haeusler (Switzerland) and Prof. Dr. Manual Sainz (Spain).

Last but not least, the authors wish to thank Prof. Dr. Irwin Stewart who stimulated our inspiration to achieve this project.

References

1. Vaewvichit K, Luangpitakchumpol P. Cochlear implantation in Thailand. *J Laryngol Otol* 1999; 113: 515-7.
2. Kanchanalarp C, Thawin Ch. Cochlear implantation. The first case report in Ramathibodi Hospital with a 22 channel electrode. *J Ramathibodi Med* 1997; 20: 73-80.
3. Fishman AJ, Roland JT Jr, Alexiades G, Mierzewski J, Cohen NL. Fluoroscopically assisted cochlear implantation. *Otol Neurotol* 2003; 24: 882-6.
4. El-Kashlan HK, Ashbaugh C, Zwolan T, Telian SA. Cochlear implantation in prelingually deaf children with ossified cochlear. *Otol Neurotol* 2003; 24: 596-600.
5. Daneshi A, Hassanzadeh S, Abasalipour P, Emamdjomeh H, Farhadi M. Cochlear implantation in Mondini dysplasia. *ORL J Otorhinolaryngol Relat Spec* 2003; 65: 39-44.
6. Francis HW, Niparko JK. Cochlear implantation update. *Pediatr Clin North Am* 2003; 50: 341-61.
7. Amatayakul P. Introduction to Audiology (Hearing Sciences). 3rd ed. Bangkok: Speech and Hearing Clinic, Ramathibodi Hospital, Faculty of Medicine, Mahidol University, 1969: 79-82.
8. Kaplan DM, Shipp DB, Chen JM, Ng AH, Nedzelski JM. Early-deafened adult cochlear implant users: assessment of outcomes. *J Otolaryngol* 2003; 32: 245-9.
9. Wang Y, Cao KL, Zheng ZY, Wang LE, Zhu XL, Wei CG, et al. Implication of cochlear implantation in patients with enlarged vestibular aqueduct syndrome. *Zhonghua Er Bi Yan Hou Ke Za Zhi* 2003; 38: 104-7.

การผ่าตัดฝังประสาทหูเทียมในเด็ก: ประสบการณ์ในไทย

ชนิดา กาญจนลาม, วิชิต ชิวเรืองโรจน์, ลลิตา เกษมสุวรรณ, เจียมจิต ถวิล, ศิริพันธ์ ศรีวันยงค์

วัตถุประสงค์: การศึกษาที่ำขึ้นเพื่อประเมินผลลัพธ์ของการผ่าตัดฝังประสาทหูเทียมในเด็กไทย ตั้งแต่ปี พ.ศ. 2542-2546

ออกแบบ: การศึกษาไปข้างหน้าแบบเปิด

สถานที่ทำการ: ภาควิชาโสต ศอ นาสิก โรงพยาบาลรามาธิบดี มหาวิทยาลัยมหิดล

วัสดุและวิธีการ: การศึกษาเปรียบเทียบผลการผ่าตัดฝังประสาทหูเทียม และการได้ยินในผู้ป่วยที่มีความผิดปกติ มอนดินี้ 2 ราย ผู้ป่วยที่มีอวัยวะรูปหอยโข่งปกติ 7 ราย และผู้ป่วยเด็กประสาทหูเสื่อมจากเยื่อหุ้มสมองอักเสบ 1 ราย

วิธีการวัดผล: ชุดการทดสอบการรับฟังเสียงแบบต่าง ๆ

ผลการศึกษา: ผู้ป่วยเด็กทั้งหมด 10 ราย 8 ราย ใช้ประสาทหูเทียมชนิดนิวเคลียส 22/24 อีก 2 รายใช้ประสาทหูเทียมของระบบเมดเอล อวัยวะรูปหอยโข่งผู้ป่วย 2 ราย มีความผิดปกติมอนดินี้ ทั้ง 2 ราย พบว่ามีน้ำพุ่งออกมาขณะทำผ่าตัด แต่ได้ผลดีหลังผ่าตัด ผู้ป่วย 8 รายที่มีอวัยวะรูปหอยโข่งปกติ และ 1 รายที่ประสาทหูเสื่อมจากเยื่อหุ้มสมองอักเสบ ในการศึกษานี้มี 3 รายที่ต้องทำการผ่าตัดฝังประสาทหูเทียมเป็นครั้งที่ 2 การพูด และการรับฟังเสียงพูดของเด็กทุกคน ดีขึ้น เด็ก 2 คนที่ได้รับการทำผ่าตัดฝังประสาทหูเทียมของระบบเมดเอลพบว่าการพูด และการรับฟังเสียงพูดได้ผลดี และเร็วกว่าเด็กที่ได้รับการทำผ่าตัดฝังประสาทหูเทียม ของระบบนิวเคลียส

สรุป: การผ่าตัดฝังประสาทหูเทียมในเด็กที่มีอวัยวะรูปหอยโข่งผิดปกติชนิดมอนดินี้ นั้น สามารถทำให้มีการพูด และการรับฟังเสียงพูดได้ผลดี จะเห็นได้ว่า ความสามารถในการรับฟังเสียงพูด ขึ้นอยู่กับอายุของเด็กขณะทำการผ่าตัด และการเตรียมการฟื้นฟูการได้ยินก่อนผ่าตัด