

Ocular Manifestations in Adolescent Cystinosis: Case Report in Thailand

Naris Kitnarong, MD*,
Prapanrat Osuwannaratana, MD**, Wasu Kamchaisatian, MD***,
Prawit Namtongthai, MD*, Ankana Metheetrairut, MD*

* Department of Ophthalmology, Faculty of Medicine, Siriraj hospital, Mahidol University

** Department of Paediatrics, Faculty of Medicine, Siriraj hospital, Mahidol University

*** Department of Paediatrics, Faculty of Medicine, Ramathibodi Hospital, Mahidol University

Three siblings with a family history of consanguinity presented with short stature and two of the patients had leg deformity. None of them experienced ocular or renal symptoms at presentation. After the pediatricians found characteristics of Fanconi syndrome, an ophthalmic consultation was requested. Ocular examination revealed typical cystine crystals deposited in the cornea and conjunctivae. No crystal deposits were found elsewhere in the eyes. Fundoscopic examination was normal. Two patients who underwent a complete ocular examination were diagnosed as adolescent cystinosis. The youngest patient who lost to follow up before completed ocular examination was suspected for adolescent cystinosis. This is the first report of cystinosis with ocular manifestation from Thailand.

Keywords: Cystinosis, Fanconi syndrome, Corneal deposit

J Med Assoc Thai 2005; 88(4): 521-6

Full text. e-Journal: <http://www.medassocthai.org/journal>

Cystinosis is a rare autosomal recessive lysosomal storage disorder characterized by the intracellular accumulation of cystine crystal in various organs. The mutation in the cystinosis gene CTNS, mapped to chromosome 17p, causes the defective transport of the amino acid cystine out of the lysosome⁽¹⁻⁵⁾. Cystinosis is diagnosed by the presence of typical cystine crystals in the cornea on slit-lamp examination or the 50 to 100 fold elevated levels of free, nonprotein cystine within polymorphonuclear leucocytes or cultured fibroblasts⁽⁶⁻⁸⁾. The demonstration of cystine crystals in macrophages in bone marrow aspiration specimens can establish the diagnosis as well^(8,9).

Three types of cystinosis have been described, including infantile (nephropathic), adolescent, and adult or ocular nonnephropathic type^(4,10). Infantile or nephropathic cystinosis is the most

common form and is characterized by Fanconi syndrome with growth retardation, renal rickets, hypokalemia, polyuria, hypothyroidism and progressive renal failure⁽¹¹⁻¹³⁾. Patients with infantile cystinosis may develop several renal tubular dysfunction during the first year of life, which, untreated may lead to end-stage renal failure and eventual death, usually before puberty^(7,14). Renal transplantation may be required by the time the patient is 10 to 13 years old⁽¹⁵⁾. Cystine accumulation has been found in kidneys, liver, spleen, bone marrow, leukocytes, lymph nodes and eyes^(7,14,16-20). Ocular manifestations include photophobia, crystal deposition in the cornea, conjunctiva, anterior chamber, and iris^(6,12, 21-25). Additional ocular findings include patchy depigmentation of the retinal pigment epithelium, mottled depigmentation of the macula that is more prominent and irregular toward the periphery^(15,24,25).

In 1971, Goldman et al reported the adolescent cystinosis⁽²⁶⁾. This type of cystinosis is characterized by the onset in the first or second decade of life with a mild nephropathy and the typical corneal and conjunctival cystine deposits, but the

Correspondence to : Kitnarong N, Department of Ophthalmology, Faculty of Medicine, Siriraj Hospital, Mahidol University, 2 Prannok, Bangkok Noi, Bangkok 11000, Thailand. Phone: 0-2419-8033, Fax: 0-2411-1906, E-mail: tenkn@mahidol.ac.th

absence of retinopathy⁽²⁶⁾. The adult or benign type cystinosis was first described by Cogan et al⁽²⁷⁾ in 1957 with the characteristic features of corneal crystal deposit, but absence or mild symptoms of photophobia^(10,26,27). The adult type has no renal involvement and is diagnosed by routine ophthalmologic examination^(10,26). The age range is from the late teens to the 50s. The life expectancy is believed to be normal^(10,26).

This report describes two patients with adolescent cystinosis and one suspected case of adolescent cystinosis in Thailand.

Case Report

Case 1

A 13-year-old Cambodian boy was admitted to the Department of Pediatrics, Faculty of Medicine, Mahidol University, Siriraj Hospital, Bangkok, Thailand with symptoms of disproportionate short stature and legs deformity. The patient had shown no characteristic symptoms of renal dysfunction. He had no ocular symptoms. Family history revealed consanguinity. His brother aged 10 years-old and sister aged 1.5 years-old also had short stature and growth retardation. His older sister, aged 15 years-old, is normal.

On physical examination at the time of admission, the patient was cooperative and of normal intelligence. He was very small for his age, measuring 126 cm (less than third percentile) and weighing 36 kg (between 10 to 25 percentile). He had bowed legs and bowed thighs with no scoliosis or kyphosis. He had normal external genitalia. After investigation for rickets, the laboratory result showed hypophosphatemia, mild metabolic acidosis, proteinuria, glucosuria and phosphaturia, which indicated generalized transport dysfunction of the proximal renal tubule, Fanconi syndrome. Ophthalmic consultation was then requested.

Ocular examination revealed visual acuity of 20/20 in both eyes. Intraocular pressure(IOP) was 15 and 14 mmHg in right and left eye respectively. No color blindness was detected by pseudoisochromatic color plate. Motility and external examination were normal. Slit lamp examination of the conjunctiva and cornea showed fine needle-like crystals in the conjunctiva and in all layers of the corneal stroma (Fig. 1A, 1B). The crystals were denser anteriorly. The peripheral cornea contained more crystal deposits, with less deposition of crystal toward the central cornea. No crystals were found in the anterior chamber or the

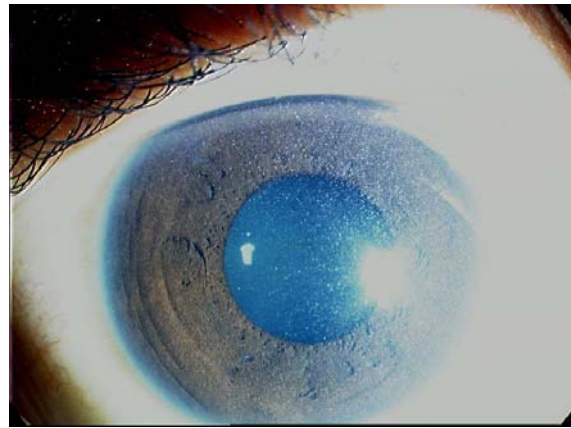


Fig. 1A Corneal photograph OS of patient case 1 showing diffuse numerous refractile cystine crystals, denser periphery

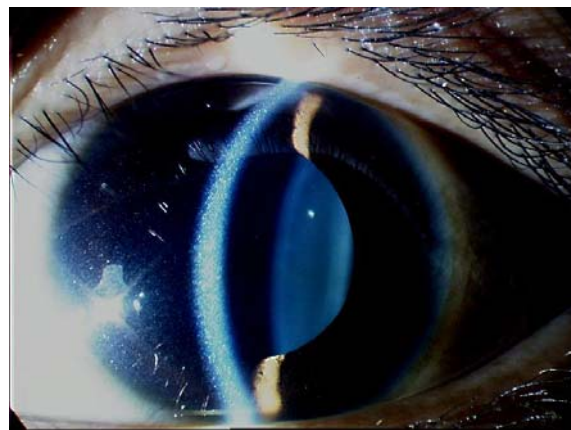


Fig. 1B Slit-lamp photograph of cornea OS from patient case 1 showing crystals deposit in all layer of stroma

iris. The lenses were clear. After dilatation with 2.5% phenylephrine hydrochloride and 1% tropicamide acetate, the pupils were fully dilated. Fundoscopic examination revealed normal macula and peripheral retina both eyes.

Case 2

A 10-year-old Cambodian boy, the younger brother of patient case 1, also had symptoms of short stature and leg deformities as his brother, but with less severity. He had neither renal dysfunction nor ocular symptoms. Physical examination found normal intelligence and good cooperation. His height was 112 cm (less than third percentile) and his weight was 28 kg (between 10 to 25 percentile) He had knock knees with normal thighs and spine. Laboratory investigation revealed Fanconi syndrome and rickets with similar

severity to case 1 but normal creatinine clearance. On ocular examination, visual acuity was 20/20 in both eyes with IOP of 16 and 14 mmHg in right and left eye respectively. No color vision impairment was detected by pseudoisochromatic color plate. Fine needle-like crystals were found deposited in the conjunctiva and cornea (Fig. 2A). The corneal crystals were more prominent in the anterior stroma and anterior to the descemet membrane compared with the posterior stroma, with a slightly clear zone between those two areas (Fig. 2B). Peripheral corneal crystals were denser than in the central cornea. No crystal deposits were found elsewhere in both eyes. Fundoscopic examination showed no abnormality.

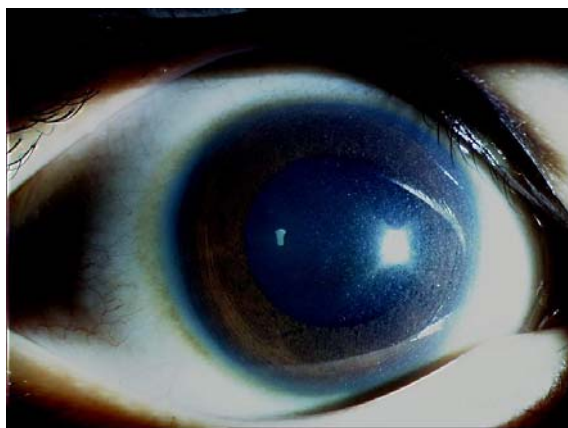


Fig. 2A Corneal photograph OD of patient case 2 demonstrating diffuse cystine crystals throughout cornea but less density comparing with the patient case 1

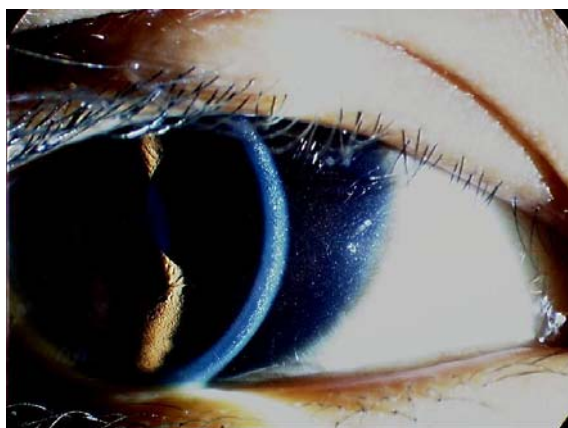

Fig. 2B Slit-lamp photograph from cornea OD of patient case 2 showing crystals in anterior stroma and a narrow zone just in front of descemet membrane with a clear zone in between

Case 3

A one and a half year-old girl presented with short stature and growth retardation. She is the youngest child in the same family as patient case 1 and 2. Her parents observed no renal or ocular symptom. The patient had normal development with proper intelligence for her age. The height measuring was 103 cm (less than the third percentile) and the weight was 12.5 kg (between 10 to 25 percentile). Knock knee was found. Laboratory investigation revealed rickets and Fanconi syndrome. The patient was lost to follow up prior to complete eye examination.

Discussion

Cystinosis was first described by Abderhalden in 1903⁽²⁸⁾. It is a rare autosomal recessive metabolic disorder resulting from mutations in the gene CTNS. Variations of CTNS mutation cause the broad spectrum of disease severity^(4,5,29). Adolescent and adult cystinosis are allelic with classic nephropathic cystinosis⁽⁴⁾. In 1941, Burki first reported the corneal crystal as an ocular manifestation associated with nephropathic cystinosis⁽³⁰⁾. Bickel et al published the histological findings of cystine crystals in the choroid in 1952⁽³¹⁾. Francois described the clinical appearance of presumed tapetoretinal degeneration in 1964⁽³²⁾. Later on, there were several reports which described ocular involvement including the choroidal and retinal changes in cystinosis^(12,13,24,33). The incidence of nephropathic cystinosis is approximately 1 in 100,000-200,000 live births⁽³⁴⁾. The highest reported prevalence of cystinosis is in parents with French-Canadian ancestry⁽¹⁵⁾. There are approximately 600 known cases in North America and 500 cases in Europe⁽³⁴⁾.

In Asia, there were only a few described cases of cystinosis, including Gadoth et al in Israel, in 1975 and Mirdehghan et al in Iraq, in 2003^(35,36). To our knowledge, these are the first reported cystinosis cases in South East Asia. The patients presented with short stature and mild to moderate Fanconi syndrome. There were no ocular or renal symptoms at the initial presentation. The diagnosis of adolescent cystinosis was established by the finding of typical cystine crystals deposits in the cornea and conjunctivae without retinal abnormality.

Generally, renal Fanconi syndrome becomes apparent 3-6 months after birth in nephropathic cystinosis and usually leads to end-stage renal disease at the age of 10 up to 20 years⁽²²⁾. Early diagnosis and treatment with renal transplantation and oral

cysteamine can change the course of this disease^(14,21,22,37,38). Renal transplantation has improved the prognosis for nephropathic cystinosis^(7,39,40). In the USA, approximately one-third of cystinosis patients have had renal transplants⁽³⁴⁾. After renal transplantation, Fanconi syndrome does not develop in the recipients and cystinosis does not recur in the graft⁽⁷⁾. However, cystine deposition continues to accumulate in non-renal tissue leading to multi-system dysfunction⁽⁷⁾. The reported long-term complications include hypothyroidism, hypogonadism, diabetes mellitus, distal myopathy, psychometric defects, memory loss, stroke-like syndrome, swallowing difficulty, gastrointestinal dysfunction, and ocular complications^(22,39,41,42).

Cysteamine (β -mercaptoethyamine) is a specific agent that has a biochemical structure similar to cysteine and can deplete cystine from the patients' cells⁽⁷⁾. Oral cysteamine, especially given before 2 years of age, has been demonstrated to lower the intracellular cystine content by 95% and has proven efficacy in delaying renal glomerular deterioration, enhancing growth, preventing hypothyroidism, and lowering muscle cystine content^(7,14,22,34,37). The dosage for cysteamine treatment is given every 6 hours with the daily dosage of 50-90 mg of free base/kg or 1.3-1.95 g of free base/m² of surface area to maintain leukocyte cystine levels to less than 1 nmol of half-cystine per mg of protein when measured five hours after a dose^(6,14,34). The common side effects of cysteamine include nausea/vomiting, anorexia, diarrhea, drowsiness, rash, and halitosis⁽³⁴⁾.

Ocular manifestations are now one of the most common complications after the successful treatment with cysteamine and renal transplantation⁽²¹⁾. Corneal crystals may be absent or minimal in the first year of life⁽⁶⁾ with progressive crystal deposition leading to gradual visual disturbance⁽⁷⁾. Photophobia and visual impairment always begin by the age of 10 years but become severe after 15 years of age⁽²¹⁾. The presented patients have demonstrated the progression of corneal crystal density with age. The patient case 1 had denser corneal crystals compared to his younger brother. The 3 patients have no ocular symptoms at present, which need long-term follow up for further complications. The reported long-term ocular complications include increasing photophobia^(6,21,43), corneal infiltration^(6,21), filamentous and band keratopathies⁽⁶⁾, decreased visual acuity^(6,21,43), impaired tritan color vision⁽⁴³⁾, reduced electroretinogram^(21,43), retinopathy⁽²¹⁾ and accumu-

lation of crystals in iris, anterior lens surface, or retina⁽⁴³⁾. Posterior synechiae with thickened stroma of iris leading to secondary glaucoma had been reported^(43,44). Visual impairment may be the result of corneal opacity or crystal deposit in retina^(21,43).

The treatment for ocular complication include supportive treatments, topical cysteamine, and corneal transplantation^(21,45,46). Systemic cysteamine has demonstrated no effect on corneal accumulation and does not improve ocular symptoms^(7,47,48). Topical cysteamine 0.5% given every 1 hour or at least 6 times a day has been shown to reduce corneal crystal deposition. Several reports found cysteamine eye drops effectively reduced photophobia and density of corneal crystals^(7,21,22). No serious side effect have been found with topical cysteamine treatment⁽⁴⁹⁾. After penetrating keratoplasty, grafts usually maintain clear with minimal crystals deposition^(45,46,50,51). The plan of management for the presented patients is to initiate early oral cysteamine treatment in all patients, especially the youngest patients, to promote growth and prevent further extra-renal organ involvement. Topical cysteamine 0.5% eye drop 6 times daily has been recommended in patient case 1.

Conclusion

Cystinosis is a rare autosomal recessive disorder with the highest incidence in French-Canadians. This is the first report in Thailand, in which the patients were diagnosed as adolescent cystinosis, an allele with nephropathic cystinosis. The characteristic of corneal crystals deposition is one of the diagnostic criteria, which is very useful and could be discovered with general slit lamp examination. Early diagnosis and treatment can improve long-term prognosis. The success of renal transplantation and oral cysteamine treatment leads to improvement of life expectancy. Extra-renal involvement, especially ocular complications, is now common.

References

1. Town M, Jean G, Cherqui S, Attard M, Forestier L, Whitmore SA, et al. A novel gene encoding an integral membrane protein is mutated in nephropathic cystinosis. *Nat Genet* 1998; 18: 319-24.
2. The Cystinosis Collaborative Research Group. Linkage of the gene for cystinosis to markers on the short arm of chromosome 17. *Nat Genet* 1995; 10: 246-8.
3. Haq MR, Kalatzis V, Gubler MC, Town MM, Antignac C, Van't Hoff WG, et al. Immunolocalization of cystinosin, the protein defective in cystinosis. *J Am Soc Nephrol* 2002; 13: 2046-51.

4. Anikster YA, Lucero C, Guo J, Huizing M, Shotelersuk V, Bernardini I, et al. Ocular nonnephropathic cystinosis: clinical, biochemical, and molecular correlations. *Pediatr Res* 2000; 47: 17-23.
5. Anikster Y, Shotelersuk V, Gahl WA. CTNS mutations in patients with cystinosis. *Hum Mutat* 1999; 14: 454-8.
6. Gahl WA, Kuehl EM, Iwata F, Lindblad A, Kaiser-Kupfer MI. Corneal crystals in nephropathic cystinosis: natural history and treatment with cysteamine eyedrops. *Mol Genet Metab* 2000; 71: 100-20.
7. Middleton R, Bradbury M, Webb N, O'Donoghue D, Van't Hoff W. Cystinosis. A clinicopathological conference. "From toddlers to twenties and beyond" Adult-Paediatric Nephrology Interface Meeting, Manchester 2001. *Nephrol Dial Transplant* 2003; 18: 2492-5.
8. Gebrail F, Knapp M, Perotta G, Cualing H. Crystalline histiocytosis in hereditary cystinosis. *Arch Pathol Lab Med* 2002; 126: 1135.
9. Varan A, Tuncer AM. The importance of the bone marrow examination in cystinosis. *Pediatr Hematol Oncol* 1991; 8: 373-4.
10. Dodd MJ, Pusin SM, Green WR. Adult cystinosis. A case report. *Arch Ophthalmol* 1978; 96: 1054-7.
11. Sanderson PO, Kuwabara T, Stark WJ, Wong VG, Collins EM. Cystinosis. A clinical, histopathologic, and ultrastructural study. *Arch Ophthalmol* 1974; 91: 270-4.
12. Francois J, Hanssens M, Coppieters R, Evens L. Cystinosis. A clinical and histopathologic study. *Am J Ophthalmol* 1972; 73: 643-50.
13. Read J, Goldberg MF, Fishman G, Rosenthal I. Nephropathic cystinosis. *Am J Ophthalmol* 1973; 76: 791-6.
14. Markello TC, Bernardini IM, Gahl WA. Improved renal function in children with cystinosis treated with cysteamine. *N Engl J Med* 1993; 328: 1157-62.
15. Richler M, Milot J, Quigley M, O'Regan S. Ocular manifestations of nephropathic cystinosis. The French-Canadian experience in a genetically homogeneous population. *Arch Ophthalmol* 1991; 109: 359-62.
16. Gahl WA, Dalakas MC, Charnas L, Chen KT, Pezeshkpour GH, Kuwabara T, et al. Myopathy and cystine storage in muscles in a patient with nephropathic cystinosis. *N Engl J Med* 1988; 319: 1461-4.
17. Gahl WA, Kaiser-Kupfer MI. Complications of nephropathic cystinosis after renal failure. *Pediatr Nephrol* 1987; 1: 260-8.
18. Charnas LR, Luciano CA, Dalakas M, Gilliatt RW, Bernardini I, Ishak K, et al. Distal vacuolar myopathy in nephropathic cystinosis. *Ann Neurol* 1994; 35: 181-8.
19. Fivush B, Green OC, Porter CC, Balfe JW, O'Regan S, Gahl WA. Pancreatic endocrine insufficiency in posttransplant cystinosis. *Am J Dis Child* 1987; 141: 1087-9.
20. Fink JK, Brouwers P, Barton N, Malekzadeh MH, Sato S, Hill S, et al. Neurologic complications in long-standing nephropathic cystinosis. *Arch Neurol* 1989; 46: 543-8.
21. Dureau P, Broyer M, Dufier JL. Evolution of ocular manifestations in nephropathic cystinosis: a long-term study of a population treated with cysteamine. *J Pediatr Ophthalmol Strabismus* 2003; 40: 142-6.
22. Geelen JM, Monnens LA, Levtchenko EN. Follow-up and treatment of adults with cystinosis in the Netherlands. *Nephrol Dial Transplant* 2002; 17: 1766-70.
23. Gahl WA. Nephropathic cystinosis. *Pediatr Rev* 1997; 18: 302-4.
24. Wong VG, Lietman PS, Seegmiller JE. Alterations of pigment epithelium in cystinosis. *Arch Ophthalmol* 1967; 77: 361-9.
25. Wong VG. Ocular manifestations in cystinosis. *Birth Defects Orig Artic Ser* 1976; 12: 181-6.
26. Goldman H, Scriver CR, Aaron K, Delvin E, Canlas Z. Adolescent cystinosis: comparisons with infantile and adult forms. *Pediatrics* 1971; 47: 979-88.
27. Cogan DG, Kuwabara T, Kinoshita J, Sheehan L, Merola L. Cystinosis in an adult. *J Am Med Assoc* 1957; 164: 394-6.
28. Abderhalden E. Familiare cystindiathese. *Hoppe Seylers Zeitschr f physiol Chemie* 1903; 38: 557-61.
29. Anikster Y, Lucero C, Touchman JW, Huizing M, McDowell G, Shotelersuk V, et al. Identification and detection of the common 65-kb deletion breakpoint in the nephropathic cystinosis gene (CTNS). *Mol Genet Metab* 1999; 66: 111-6.
30. Burki E. Ueber die Cystinkrankheit im Kleinkindesalter unter besonderer Berücksichtigung des Augenbefundes. *ophthalmologica* 1941; 101: 257.
31. Bickel H. Cystine storage disease with aminoaciduria and dwarfism; Lignac-Fanconi disease. *Acta Paediatr* 1953; 42: 581-5.
32. Francois J. Hereditary chorioretinal degeneration and metabolic disturbances. *Int Ophthalmol Clin* 1968; 8: 911-27.
33. Feature photo. Cystinosis with extensive choroidal involvement. *Arch Ophthalmol* 1965; 74: 868-9.
34. Anikster Y, Lucero C, Touchman JW, Huizing M, McDowell G, Shotelersuk V, et al. Steady-state pharmacokinetics and pharmacodynamics of cysteamine bitartrate in paediatric nephropathic cystinosis patients. *Br J Clin Pharmacol* 2003; 56: 520-5.
35. Gadoth N, Moses SW, Boichis N. Cystinosis in Israel. *Harefuah* 1975; 88: 113-4.
36. Mirdehghan M, Ahmadzadeh A, Bana-Behbahani M, Motlagh I, Chomali B. Infantile cystinosis. *Indian Pediatr* 2003; 40: 21-4.
37. Gahl WA. Early oral cysteamine therapy for nephropathic cystinosis. *Eur J Pediatr* 2003; 162 Suppl 1: S38-41.
38. McDowell GA, Town MM, van't Hoff W, Gahl WA. Clinical and molecular aspects of nephropathic cysti-

- nosis. *J Mol Med* 1998; 76: 295-302.
39. Theodoropoulos DS, Krasnewich D, Kaiser-Kupfer MI, Gahl WA. Classic nephropathic cystinosis as an adult disease. *JAMA* 1993; 270: 2200-4.
 40. Ehrich JH, Brodehl J, Byrd DI, Hossfeld S, Hoyer PF, Leipert KP, et al. Renal transplantation in 22 children with nephropathic cystinosis. *Pediatr Nephrol* 1991; 5: 708-14.
 41. Ehrich JH, Wolff G, Stoeppler L, Heyer R, Offner G, Brodehl J. Psychosocial intellectual development of children with infantile cystinosis and cerebral atrophy (author's transl). *Klin Padiatr* 1979; 191: 483-92.
 42. Ehrich JH, Stoeppler L, Offner G, Brodehl J. Evidence for cerebral involvement in nephropathic cystinosis. *Neuropediatric* 1979; 10: 128-37.
 43. Kaiser-Kupfer MI, Caruso RC, Minkler DS, Gahl WA. Long-term ocular manifestations in nephropathic cystinosis. *Arch Ophthalmol* 1986; 104: 706-11.
 44. Wan WL, Minckler DS, Rao NA. Pupillary-block glaucoma associated with childhood cystinosis. *Am J Ophthalmol* 1986; 101: 700-5.
 45. Kaiser-Kupfer MI, Datiles MB, Gahl WA. Corneal transplant in boy with nephropathic cystinosis. *Lancet* 1987; 1: 331.
 46. Kaiser-Kupfer MI, Datiles MB, Gahl WA. Clear graft two years after keratoplasty in nephropathic cystinosis. *Am J Ophthalmol* 1988; 105: 318-9.
 47. Gahl WA, Reed GF, Thoene JG, Schulman JD, Rizzo WB, Jonas AJ, et al. Cysteamine therapy for children with nephropathic cystinosis. *N Engl J Med* 1987; 316: 971-7.
 48. Cantani A, Giardini O, Ciarella Cantani A. Nephropathic cystinosis: ineffectiveness of cysteamine therapy for ocular changes. *Am J Ophthalmol* 1983; 95: 713-4.
 49. Tsilou ET, Thompson D, Lindblad AS, Reed GF, Rubin B, Gahl W, et al. A multicentre randomised double masked clinical trial of a new formulation of topical cysteamine for the treatment of corneal cystine crystals in cystinosis. *Br J Ophthalmol* 2003; 87: 28-31.
 50. Katz B, Melles RB, Schneider JA. Crystal deposition following keratoplasty in nephropathic cystinosis. *Arch Ophthalmol* 1989; 107: 1727-8.
 51. Katz B, Melles RB, Schneider JA. Recurrent crystal deposition after keratoplasty in nephropathic cystinosis. *Am J Ophthalmol* 1987; 104: 190-1.

อาการทางตาของผู้ป่วยโรคซิสติโนสิสในวัยรุ่น

นริศ กิจณรงค์, ประพานรัตน์ ไอสวรรณรัตน์, วสุ กำชัยเสถียร, ประวิทย์ น้ำทองไทย, อังคณา เมธีไตรรัตน์

ผู้ป่วยเด็กชายสามคน อายุ 3 ราย เข้ารับการตรวจรักษาที่ภาควิชากุมารเวชศาสตร์ คณะแพทยศาสตร์ ศิริราชพยาบาล มหาวิทยาลัยมหิดล ด้วยอาการตัวเตี้ยและขาคีบผิดปกติ ประวัติครอบครัวพบบิดา มารดาเป็นญาติกัน ผลการตรวจร่างกายทั่วไปและการตรวจทางห้องปฏิบัติการเข้าได้กับกลุ่มอาการ Fanconi syndrome ผู้ป่วยทั้ง 3 ราย ได้ถูกส่งปรึกษาเพื่อรับการตรวจทางจักษุวิทยา ที่ภาควิชาจักษุวิทยา ผลการตรวจตาพบผลึก Cystine ในกระจกตาและเยื่อตาขาว แต่ไม่พบความผิดปกติที่จอประสาทตา ผลึก Cystine ในกระจกตา และเยื่อตาขาว เป็นลักษณะเฉพาะของโรค Cystinosis ผู้ป่วย 2 รายที่ได้รับการตรวจทางจักษุวิทยาจึงได้รับการวินิจฉัยว่าเป็นโรค Adolescent Cystinosis ส่วนผู้ป่วยอีกราย ขาดการติดตามการรักษา ก่อนได้รับการตรวจทาง จักษุวิทยา ก็ได้รับการสงสัยว่าเป็นโรค Adolescent Cystinosis เช่นกัน การรายงานผู้ป่วยฉบับนี้ นับเป็นการรายงานผู้ป่วย Cystinosis ครั้งแรกในประเทศไทย