

Effectiveness of Combined Antibiotic Ophthalmic Solution in the Treatment of Hordeolum after Incision and Curettage: A Randomized, Placebo-Controlled Trial: A Pilot Study

Parima Hirunwiwatkul, MD*,
Kanitta Wachirasereechai, MD*

*This paper was presented at the Asia Pacific Academy of Ophthalmology on
December 2, 2003, Bangkok, Thailand*

** Department of Ophthalmology, Faculty of Medicine, Chulalongkorn University*

The presented pilot study compared the effectiveness of combined antibiotic ophthalmic solution (neomycin sulfate, polymyxin B sulfate and gramicidin) with a placebo (artificial tear) in the treatment of hordeolum after incision and curettage (I&C). A randomized, placebo-controlled trial with patients and investigators blinded from the start started from June 2002 to May 2003. Subjects were patients with untreated hordeolum who subsequently underwent I&C at the Ophthalmology Department. The patients were randomized into 2 groups: group A for combined antibiotic ophthalmic solution, and group B for artificial tear containing the antibiotic solution base. Pain score, mass size and duration of cure were recorded before and on the 3rd and 7th day after treatment. The study included 14 patients in each group. Two subjects in group A and three subjects in group B dropped out. There were no statistically significant differences of all outcomes in both groups, even with the intention-to-treat analysis. The conclusion is combined antibiotic ophthalmic solution is not more effective than placebo in the treatment of hordeolum after I&C.

Keywords: *Hordeolum, Antibiotic, Artificial tear, Incision and curettage*

J Med Assoc Thai 2005; 88(5): 647-50

Full text. e-Journal: <http://www.medassocthai.org/journal>

Hordeolum is a common inflammatory disease of the eyelids. The patients present with an acute infection as a localized area of redness, tenderness and swelling near the lid margin⁽¹⁾. The disease may involve the glands of Zeis and Moll (external hordeolum) or meibomian gland (internal hordeolum)^(1,2). Common causative organisms are staphylococcus species⁽³⁾. Spontaneous resolution often occurs. The assiduous application of warm compresses and topical antibiotics is usually curative if any treatment is needed⁽³⁾. In some cases, however, the disease may progress, and as a result surgical incision and curettage (I&C) may then be required. Antibiotics may prevent infection of surrounding lash follicles⁽⁴⁾. Simple hordeolum is a cyst of pus. Because of its self-limitation, only I&C can remove

Correspondence to : Hirunwiwatkul P, Department of Ophthalmology, Faculty of Medicine, Chulalongkorn University, Bangkok 10330, Thailand.

the causative bacteria by pus drainage. Antibiotic use after drainage is controversial in simple cases. Topical broad-spectrum antibiotics may be needed for complicated hordeolum after I&C or for recurrent cases⁽⁵⁾.

The role of antibiotics after incision and curettage at King Chulalongkorn Memorial Hospital remains unclear and usually depends on the preference of practicing ophthalmologists. The purpose of the present study was to evaluate the effectiveness of a combined antibiotic ophthalmic solution (neomycin sulfate, polymyxin B sulfate and gramicidin) in the treatment of simple hordeolum after incision and curettage.

Material and Method

All newly diagnosed, untreated hordeolum patients who subsequently underwent incision and curettage at the outpatient department of ophthalmology, King Chulalongkorn Memorial Hospital, were

recruited from May 2002 to June 2003. The present study included patients who had at least 5-millimeters hordeolum, with the onset within 7 days, had never used any antibiotic treatment following the onset and underwent the incision and curettage under local anesthesia. The exclusion criteria were patients who had previous incision and curettage of the same site within 1 month, I&C more than 3 times or lesions in the adjacent areas suggesting complications associated with hordeolum such as preseptal cellulitis or blepharitis. Also excluded were patients with immunodeficiency, history of bleeding tendency or allergic to aminoglycoside, polymyxin B, gramicidin, xylocaine and povidone iodine.

The present study has been approved by the Ethics Committee, Faculty of Medicine, Chulalongkorn University. Written informed consent was obtained from each subject. The demographic data, pain score and mass size were recorded before treatment. Incision and curettage was done under sterile technique and local anesthesia using subcutaneous 2% xylocaine injection. Randomization codes were generated by the block-of-four technique. The allocation sequence was kept by a research assistant. The patients were divided into two groups: group A received combined neomycin sulfate, polymyxin B sulfate and gramicidin ophthalmic solution (Polyoph) four times daily; group B received artificial tear (Lacoph), which contained the same components of Polyoph but without antibiotics, four times daily. Both investigators and patients were masked.

The patients were followed up on the 3rd and 7th day after treatment. Pain score, mass size and duration of cure were assessed. Pain score was defined as the primary outcome using a numerical verbal rating scale, where 0 is no pain and 10 is the maximum tolerable pain. Mass size was measured in millimeters using a standard caliper. Duration of cure was defined the number of days from the day of incision to the day free of the disease. Disease-free was defined by the disappearance of the discomfort and/or the mass, depending on the patient's judgment. If the patients

did not feel cured on day 7, the assessment was then repeated at day 30. In the cases that they could not be followed up at the hospital, data were collected by telephone. The treatment complications and adverse drug reactions were recorded. The pain score and mass size were analyzed using the Mann-Whitney U test. The duration of cure for both groups was plotted on a survival curve and compared, using the Kaplan-Meier analysis. A p-value ≤ 0.05 was considered statistically significant.

Results

From June 2002 to May 2003, 455 newly diagnosed patients with hordeolum were presented. Of this, 427 were excluded. Most of the excluded cases had used a topical or systemic antibiotic prior to their first visit. Only 28 patients met the inclusion criteria. As a result, there were fourteen patients in each group. Twelve cases had no pain at baseline (7 in group A and 5 in group B). Mean pain score in group A and B was 2.07 ± 2.55 and 2.79 ± 2.49 , respectively. The average mass size was 6.21 ± 1.44 millimeters in group A and 6.39 ± 2.30 millimeters in group B. The pain score and mass size baseline were not different between the two groups before treatment ($p = 0.336$ in pain and 0.796 in mass). Four patients, two in each group, were lost to follow-up. One patient in group B had co-intervention with oral Dicloxacillin. No complication or adverse drug reaction occurred in both groups.

On the third day after treatment, all but two patients reported no pain. Both patients in group A, had increased their pain score from 5 to 6 and 3 to 5. The size of mass is shown in Table 1. There was no significant difference between the duration of cure in both groups ($p = 0.988$). The survival curve is shown in Fig. 1. Pain scores of the two groups were compared by intention-to-treat analysis (worst-case scenario), using the pain score at 10 in the treatment group and at 0 in the placebo group. For the mass size, the worst mass size in the treatment group is supposed to be double the mass size before treatment compared to no

Table 1. Means, standard deviation and p-value of hordeolum mass (in millimeters) before treatment, 3rd and 7th after treatment (follow up)

Size of mass	Before treatment (mean \pm SD)	3 rd day follow up (mean \pm SD)	7 th day follow up (mean \pm SD)
Group A (Antibiotics) (n = 14)	6.39 \pm 2.30	2.54 \pm 2.81	1.46 \pm 2.62
Group B (No antibiotic) (n = 14)	6.21 \pm 1.44	2.14 \pm 1.87	1.74 \pm 2.23
p-value	0.796	0.490	0.634

Table 2. Grading of pain severity before treatment, 3rd and 7th day after treatment (follow up), using intent-to-treat analysis (worst-case scenario)

Pain score	Before treatment (mean ± SD)	3 rd day follow up (mean ± SD)	7 th day follow up (mean ± SD)
Group A (Antibiotics)	2.07±2.56	1.50±3.16	0.71±2.67
Group B (No antibiotic)	2.79±2.49	0.00	0.00
p-value	0.336	0.072	0.317

Table 3. Show hordeolum mass size (in millimeters) before treatment, 3rd and 7th day after treatment (follow up), using intent-to-treat analysis (worst-case scenario)

Size of mass	Before treatment (mean ± SD)	3 rd day follow up (mean ± SD)	7 th day follow up (mean ± SD)
Group A (Antibiotics)	6.50±2.30	3.43±3.90	2.5±4.24
Group B (No antibiotic)	6.21±1.44	1.71±1.90	1.43±2.10
p-value	0.796	0.465	0.779

mass appearance in the placebo group. All results are shown in Table 2 and 3; durations of cure are not different ($p = 0.2652$) in Fig. 2. There was no statistically significant difference of all outcomes.

Discussion

Hordeolum is a common disease in outpatient settings. The pathophysiology of the disease comprises two major grounds: the obstruction of the sebaceous gland around the eyelids and the subsequent infection on these glands. Some hordeolum spontaneously resolve. Most simple cases can be cured with pus drainage alone. The authors reviewed literatures but no literature about this was found. The role of an antibiotic after incision and curettage is still

not known, however, the prescription of antibiotic after the incision and curettage is not uncommon in general practices. Inappropriate use of antibiotics may lead to inadvertent side effects, antibiotic resistance and unnecessary financial expense.

The objective to study the effectiveness of the antibiotic eye drop after hordeolum drainage was followed in the present study. The authors could not calculate the number of sample size in the present study because of no pilot study in treatment hordeolum between antibiotics and placebo. Then the authors planned to study for 1 year. With strict inclusion criteria, patients who received any kind of prior antibiotic were excluded as the previous treatment might interfere with the outcome. Since the disease is

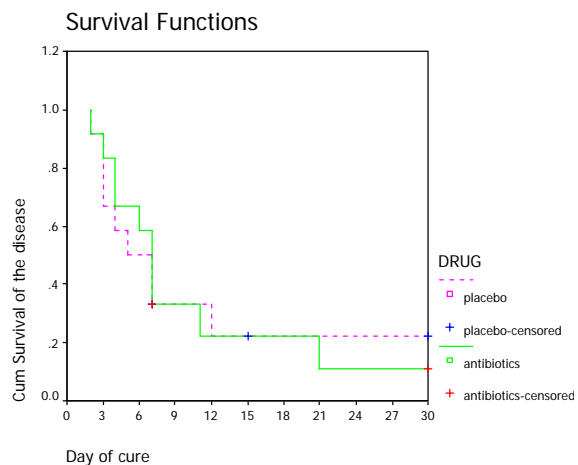


Fig. 1 Survival curve of both groups

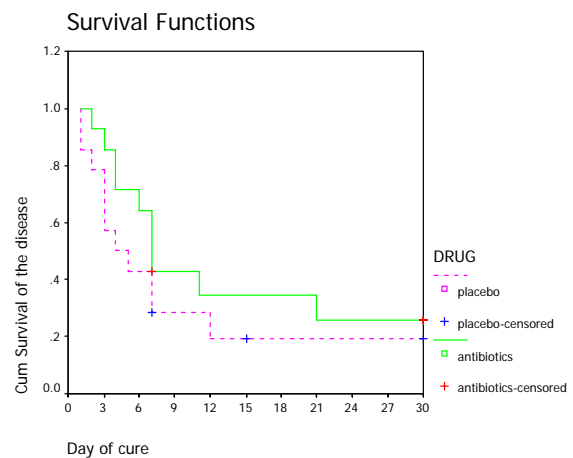


Fig. 2 Survival curve of both groups, using intent-to-treat analysis (worst-case scenario)

mild and common, patients tend to see general practitioners or pharmacies for initial treatment before considering tertiary care hospitals. As a result, only 28 (6.15%) out of 455 hordeolum patients were recruited in the present study. The results from the present study may, therefore, have a limitation on the external validity.

The baseline characteristics of the patients in both groups were comparable. The outcome variables after eye drop prescription were not statistically different. Since there were several patients who did not adhere to the protocol and four patients were lost to follow-up, the worst-case scenario was assumed and applied the intention-to-treat analysis, concerning which there was no statistical significance.

The differences of the outcome between the two groups of patients were not detected. This may be due to the small sample size or the ineffectiveness of the antibiotic when compared with the placebo. The authors get these data to calculate the appropriate sample size for next study. In the near future, a study of the role of antibiotics after I&C in a larger study sample with a less strict eligibility criteria would answer the questions more clearly.

Acknowledgements

The present study was supported financially by "The grants for development of new faculty staff, Ratchadapiseksompotch fund" from Chulalongkorn University. The authors wish to thank Assistant Professor Wasee Tulvatana for reviewing the manuscript.

References

1. Bartlett JD, Melore GG. Inflammatory disease. In: Bartlett JD, Jaanus SD, eds. Clinical ocular pharmacology. 3rd ed. Newton, MA: Butterworth, 1995: 564-5.
2. Bezan DJ. Hordeolum. In: Roberts DK, Jerry JE, eds. Ocular disease diagnosis and treatment. 2nd ed. Newton, MA: Butterworth, 1996: 466.
3. Eyelid inflammation. In: Basic and clinical science course section 7. San Francisco, CA: American Academy of Ophthalmology, 2000: 142.
4. Trevor-Roper PD. Diseases of the eyelids. Int Ophthalmol Clin 1974; 14: 362-93.
5. Fraunfelder FT. Hordeolum. In: Fraunfelder FT, Roy FH, eds. Current ocular therapy. 4th ed. Philadelphia: Saunders, 1995: 578-9.
6. Hudson RL. Treatment of styes and meibomian cysts. Practical procedures. Aust Fam Phys 1981; 10: 714-7.

ผลของยาหยอดตาปฏิชีวนะผสมในการรักษาต่อมไขมันใต้เปลือกตาอักเสบ (กุ้งยิง) ภายหลังการผ่าตัดระบายหนอง: การศึกษาแบบทดลองชนิดมีกลุ่มควบคุมและสุ่มแยกกลุ่ม

พริมา หิรัญวิวัฒน์กุล, ชนิษฐา วชิรเสรีชัย

การศึกษาเปรียบเทียบผลของยาหยอดตาปฏิชีวนะผสม กับ ยาหยอดตาที่ไม่มีส่วนของยาปฏิชีวนะในการรักษาต่อมไขมันใต้เปลือกตาอักเสบ (กุ้งยิง) ภายหลังการผ่าตัดระบายหนอง โดยเป็นการศึกษาแบบทดลองชนิดมีกลุ่มควบคุมและสุ่มแยกกลุ่มโดยปิดบังชนิดของการรักษาแก่ผู้ป่วยและผู้วิจัย เริ่มทำการศึกษาเดือนมิถุนายน 2545 ถึง พฤษภาคม 2546 ในผู้ป่วยโรคกุ้งยิงซึ่งไม่เคยได้รับการรักษามาก่อนที่ได้รับการรักษาโดยการผ่าตัดระบายหนองที่ห้องตรวจจักษุวิทยา ผู้ป่วยถูกสุ่มแบ่งเป็น 2 กลุ่ม กลุ่มแรกได้รับการรักษาด้วยยาหยอดตาปฏิชีวนะ ส่วนอีกกลุ่มได้รับยาน้ำตาเทียมซึ่งมีส่วนผสมเหมือนกับยากลุ่มแรกแต่ไม่มียาปฏิชีวนะ ระดับความเจ็บ ขนาดของก้อน และระยะเวลาของการหายจากโรค ก่อนและหลังการรักษาถูกนำมาวิเคราะห์ การศึกษานี้รวบรวมผู้ป่วยได้กลุ่มละ 14 คน ผู้ป่วยหายไประหว่างการรักษาในกลุ่มแรก 2 คน กลุ่มหลัง 3 คน หลังวิเคราะห์ไม่พบความแตกต่างอย่างมีนัยสำคัญทางสถิติของผลของการรักษา ดังนั้นการให้ยาหยอดตาปฏิชีวนะผสม ไม่มีผลต่อการรักษาโรคกุ้งยิงภายหลังการผ่าตัดระบายหนองเมื่อเทียบกับยาหยอดตาที่ไม่มีส่วนของยาปฏิชีวนะ