

Translaryngeal Retrograde Wire-guided Fiberoptic Intubation for Difficult Airway: A Case Report

Waraporn Chau-In, MD*,
Suthida Pongmetha, MD*, Krisna Sumret*,
Patravoot Vatanasapt, MD**, Waranyoo Khongkankong***

* Departments of Anesthesiology, Faculty of Medicine, Khon Kaen University, Khon Kaen

** Departments of Otolaryngology, Faculty of Medicine, Khon Kaen University, Khon Kaen

*** Department of Oral and Maxillofacial Surgery, Faculty of Dentistry, Khon Kaen University, Khon Kaen

The authors describe the special tracheal intubation technique used in two patients with a difficult airway. These are the translaryngeal retrograde wire-guided and fiberoptic intubation. The authors show how to use both to facilitate intubation. The authors modified the technique by passing a guide-wire in a retrograde manner from the trachea to the nose and then a fiberoptic laryngoscope within the endotracheal tube over the wire. The technique can be applied for use in any difficult airway situation.

Keywords: Intubation technique, Difficult airway, Retrograde wire-guided, Fiberoptic

J Med Assoc Thai 2005; 88(6): 845-8

Full text. e-Journal: <http://www.medassocthai.org/journal>

Tracheal intubation in patients with anatomical abnormalities of the head and neck requires superior skill and use of special intubation techniques, one of which is translaryngeal retrograde wire-guided intubation.

Translaryngeal retrograde wire-guided intubation was first described by Butler and Cirillo in 1960, and is often used effectively in cases where intubation has proven difficult⁽¹⁾. Subsequent modifications of the technique include the use of a fiberoptic bronchoscope to permit tracheal intubation under direct observation⁽²⁾. Waraporn et al (1999) modified equipment for translaryngeal retrograde wire-guided intubation in Department of Anesthesiology, Faculty of Medicine, Khon Kaen University⁽³⁾, but encountered problems while passing the endotracheal tube over the guide-wire into the larynx. The authors modified this technique for a recent case by passing the guide-wire in a retrograde manner from the trachea to the nose and then passing a fiberoptic laryngoscope within an endotracheal tube over the wire.

With approval from the institutional Ethics Committee and informed written consent from

Correspondence to : Chau-In W, Departments of Anesthesiology, Faculty of Medicine, Khon Kaen University, Khon Kaen 40002, Thailand.

the patients, the authors would like to report the experiences in using a fiberoptic laryngoscope to assist in translaryngeal retrograde wire-guided intubation for two patients with difficult airway. Published reports of translaryngeal retrograde wire-guided fiberoptic intubation are also reviewed.

Case Report

Case 1

A 33-year-old, 48.7-kg Thai male was admitted for external ethmoidectomy. He had experienced a failed attempt at orotracheal intubation for a nasal mass biopsy one month before. The pathological report of the biopsy by local anesthesia was carcinoma of the maxilla.

The preoperative assessment showed normal vital signs, normal blood tests (ASA class I) and a normal mouth opening (Mallampati's classification 2). The mentosternal length was 17 cm - within the normal limit - but the mentothyroid length was 5 cm, which is shorter than normal and may be the probable cause of the previous difficult intubation. Due to the possibility of difficulty with a standard laryngoscope and intubation, a fiberoptic laryngoscope was planned. The patient's past medical history was negative.

A fiberoptic laryngoscope intubation, under local anesthesia, intravenous morphine and supplemental oxygen was attempted for thirty minutes but failed. A cricothyroidotomy via an IV catheter was then performed under local anesthesia and a 60-cm 0.032-inch guide-wire passed, cephalad, through the catheter retrograde to the mouth opening. The endotracheal tube could not pass over the guide-wire because of a too anterior cord. The authors then employed a fiberoptic laryngoscope to proceed. The well-lubricated 7.5-mm endotracheal tube was passed over the fiberoptic laryngoscope and the guide-wire, in a retrograde fashion, through the suction port of the fiberoptic. The fiberoptic laryngoscope and the endotracheal tube were then passed through the larynx and intubation was accomplished (Fig. 1). The fiberoptic laryngoscope and guide-wire were removed and the external ethmoidectomy proceeded uneventfully.

Case 2

A 40-year-old, 45-kg female was scheduled for orthognathic surgery for corrective jaw deformities. Her vital signs and blood tests were normal (ASA class I). She had a normal mouth opening (Mallampati's classification 2). The mentothyroid length was 4.5 cm - shorter than normal (Fig. 2). Conscious intubation using standard laryngoscopy could not visualize the vocal cords and intubation under fiberoptic laryngoscopy failed. Successful translaryngeal retrograde intubation was performed using the wire-guided fiberoptic laryngoscope technique.

Discussion

Since a difficult airway situation is dangerous and requires proper and immediate management to correct hypoxia, assessment for potentially difficult intubation is prudent. History is documented followed

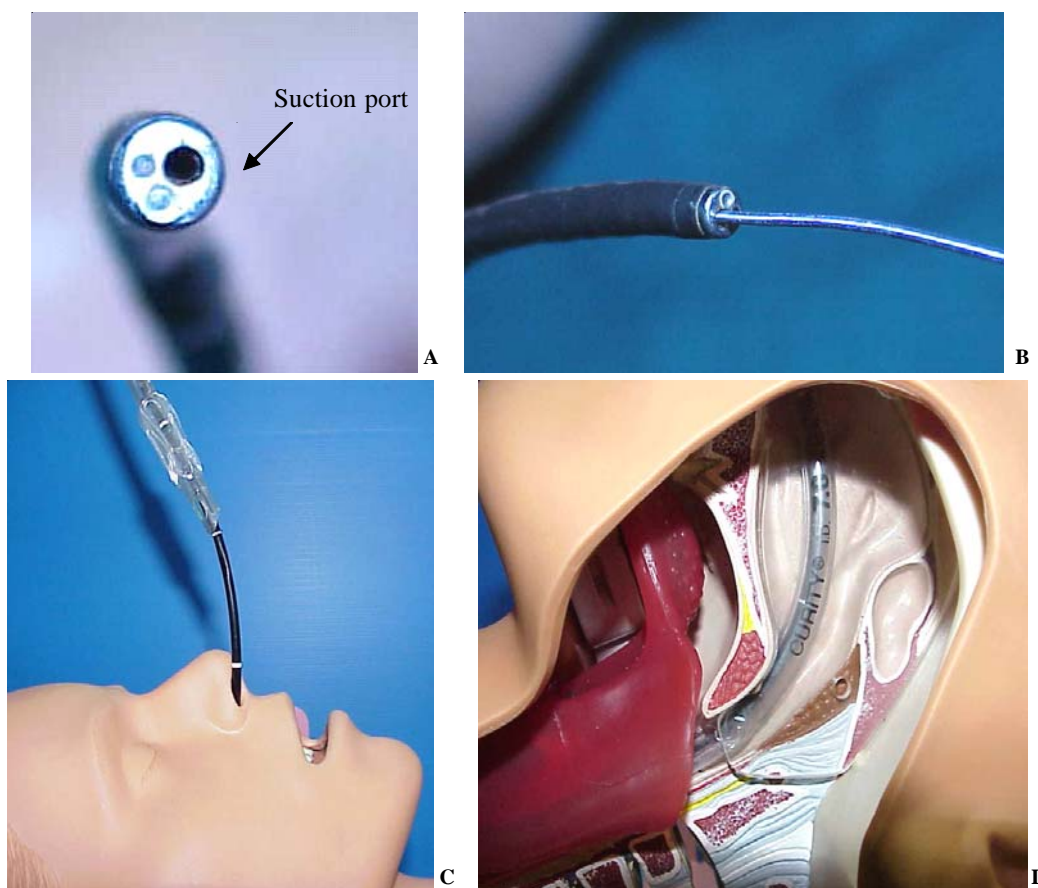


Fig. 1 (A, B) Shows how to pass the guide wire retrograde through the suction port of the fiberoptic laryngoscope (C) An endotracheal tube passes over the fiberoptic along wire-guided and then through the larynx (D)

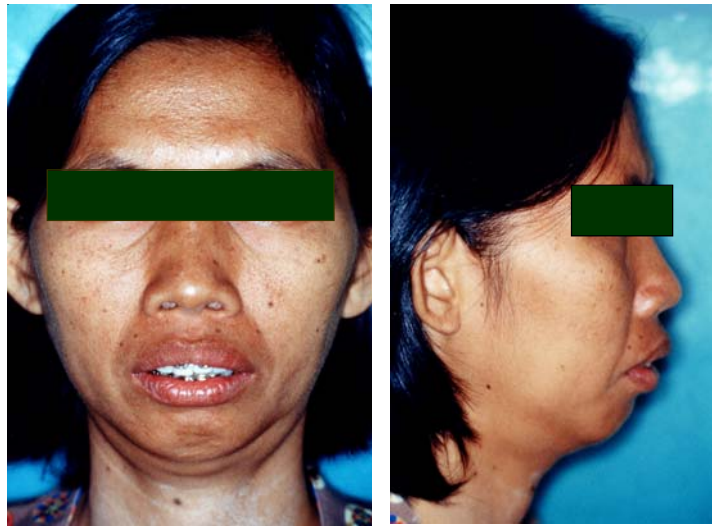


Fig. 2 Anterior and lateral view of the patient (case 2) with the 5-cm mentothyroid-distance

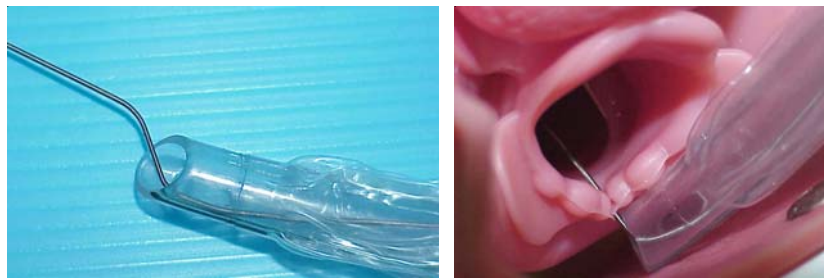


Fig. 3 Kinking of the guide-wire at the arytenoid cartilage

by a physical examination of the anatomy of the oral cavity, larynx and cervical spine mobility. If a difficult airway is foreseen, fiberoptic intubation should be attempted first. But, should this approach fail, trans-laryngeal retrograde wire-guided intubation should follow. However, advancement of a tracheal tube over a guide-wire is often impeded by kinking at the arytenoid cartilage (Fig. 3). In the event that both techniques fail, the hypoxia can be corrected by transtracheal jet ventilation, laryngeal mask airway, esophageal-tracheal combitube™ or surgery⁽⁴⁾.

Fiberoptic translaryngeal retrograde guided-wire intubation is a useful technique for intubation of a difficult airway. Possible complications⁽⁵⁾ include hematoma from injury to the cricothyroid artery⁽⁶⁾, subcutaneous emphysema⁽⁷⁾ along the guide-wire tract.

The presented technique used a modified, 60-cm-long, CVP guide-wire, different from Gupta (1989), who used a 125-cm guide-wire cannulated

through a fiberoptic suction port⁽⁸⁾ and Lechman, who used a 150-cm Teflon-coated J-wire cannulated through the bronchoscopy biopsy port⁽²⁾. Bissinger applied the technique to patients with laryngeal carcinoma^(9,10). Rosenblatt applied fiberoptic bronchoscope retrograde from the cricothyroid membrane then passed the guide-wire through the nose and introduced the endotracheal tube antegrade into the vocal cords⁽¹¹⁾. Robert passed the fiberoptic bronchoscope along the retrograde guide-wire⁽¹²⁾. Audenaert used the technique with pediatric patients with a difficult airway⁽¹³⁾.

Bowes reported pneumomediastinum, post translaryngeal retrograde wire-guided fiberoptic intubation was a minor complication and spontaneous remission occurred within 7 days⁽¹⁴⁾. The second patient in the present report had subcutaneous emphysema around the neck, which disappeared after inflation of a tracheal cuff. There were no other post-operative complications in either case prior to their being discharged from hospital.

Conclusion

The authors' adapted technique proved practical and safe, and appears to have qualitative advantages over retrograde and fiberoptic techniques used alone in patients refractory to intubation. The authors suggest translaryngeal retrograde wire-guided fiberoptic intubation as a valuable addition to present methods of securing a difficult airway. Learning the technique under controlled situations allows the development of skills needed during emergency conditions.

Acknowledgments

The authors wish to thank Mr. Niwat Sumret who proofread the report and Mr. Bryan Roderick Hamman for assistance with the English editing.

References

1. Butler FS, Cirillo AA. Retrograde tracheal intubation. *Anesth Analg* 1960; 39: 333-8.
2. Lechman MJ, Donahoo JS, Macvaugh H III. Endotracheal intubation using percutaneous retrograde guide-wire insertion followed by antegrade fiberoptic bronchoscope. *Crit Care Med* 1986; 14: 589-90.
3. Chau-In W, Tribudharat S. Translaryngeal intubation technique. *Thai J Anesthesiol* 1999; 25: 212-6.
4. Levitan RM, Kush S, Hollander JE. Device for difficult airway management in academic emergency departments. *Ann Emerg Med* 1999; 33: 694-8.
5. Wijesinghe HS, Gough JE. Complications of a retrograde intubation in trauma patient. *Acad Emerg Med* 2000; 7: 1267-71.
6. Shantha TR. Retrograde intubation using the subcricoid region. *Br J Anaesth* 1992; 68: 109-12.
7. Bainton CR. Cricothyrotomy. *Int Anesthesiol Clin* 1994; 31: 95-108.
8. Gupta B, McDonald JS, Brooks JHJ, Mendenhall J. Oral fiberoptic intubation over a retrograde guide-wire. *Anesth Analg* 1989; 68: 517-9.
9. Bissinger U, Buggenberger H, Lenz G. Retrograde-guided fiberoptic intubation in patients with laryngeal carcinoma. *Anesth Analg* 1995; 81: 408-10.
10. Eidelman LA, Pizov R. A safer approach to retrograde-guided fiberoptic intubation. *Anesth Analg* 1996; 82: 1107-13.
11. Rosenblatt WH, Angood PB, Marsnets I, Kaklamanos IG, Garwood S. Retrograde fiberoptic intubation. *Anesth Analg* 1997; 84: 1142-4.
12. Robert RW, Solgonick RM. A modification of retrograde wire-guided, fiberoptic-assisted endotracheal intubation in a patient with ankylosing spondylitis. *Anesth Analg* 1996; 82: 1290-1.
13. Audenaert SM, Montgomery CL, Stone B, Akin RE, Lock RL. Retrograde-assisted fiberoptic tracheal intubation in children with difficult airways. *Anesth Analg* 1991; 73: 660-4.
14. Bowes WA III, Johnson JO. Pneumomediastinum after planned retrograde fiberoptic intubation. *Anesth Analg* 1994; 78: 795-7.

การใส่ท่อช่วยหายใจโดยเทคนิค *Translaryngeal retrograde wire-guided fiberoptic* สำหรับผู้ป่วยที่มีภาวะใส่ท่อช่วยหายใจลำบาก

วารสารณั้ เชื้ออินทร์, สุธิดา พงษ์เมธา, กฤษณา สำเร็จ, ภัทรวุฒิ วัฒนศัพท์, วรัญญู คงกันคง

รายงานผู้ป่วยที่มีภาวะใส่ท่อช่วยหายใจลำบาก 2 รายที่ได้รับกรั้ให้ยาระงับความรู้สึกแบบใส่ท่อช่วยหายใจโดยใช้เทคนิคผสมระหว่าง *translaryngeal retrograde wire-guided* รวมกับการใช้ *fiberoptic* แสดงวิธีดัดแปลงการใช้ *wire-guided* ที่ใส่ผ่านย่อนจาก *translarynx* ออกทางจมูกแล้วสอดเข้าทาง *suction port* ของ *fiberoptic laryngoscope* เพื่อช่วยให้การใส่ท่อช่วยหายใจเข้าหลอดคอง่ายขึ้น ใช้เมื่อเกิดปัญหาในการผ่านท่อเข้าหลอดคอง่าน *wire-guided* โดยตรงไม่ได้