

Primary Peritoneal Adenosarcoma with Stromal Overgrowth and Fetal Type Cartilage: A Case Report and Literature Review

Samornmas Kanngurn, MD*,
Julintorn Somran, MD**, Chartchai Art-ong, MD***,
Wisut Lamlerthton, MD****, Suchat Porncharoenpong, MD*****

* Department of Pathology, Faculty of Medicine, Prince of Songkla University

** Department of Pathology and Forensic Medicine, Naresuan University

*** Department of Obstetrics and Gynecology, Buddhachinaraj Hospital

**** Department of Medicine, Buddhachinaraj Hospital

***** Department of Anatomical Pathology, Buddhachinaraj Hospital, Phitsanuloke

Primary peritoneal adenosarcoma with sarcomatous overgrowth and fetal-type cartilage presented in a 48-year-old female patient is described. The tumor seems likely to have derived from the pelvic peritoneum, whereas the uterus, ovaries and tubes were uninvolved. It was composed of benign-appearing glands and a sarcomatous component showing cartilaginous differentiation. The extrauterine adenosarcomas were reported in other sites, e.g. cervix, ovary, fallopian tube, bladder, and peritoneum. This case was the ninth case of the primary peritoneal adenosarcoma in the English literature and the first report in Thailand.

Keywords: Peritoneal adenosarcoma, Stromal overgrowth, Fetal-type cartilage, Mixedmesodermal tumor

J Med Assoc Thai 2005; 88(6): 849-54

Full text. e-Journal: <http://www.medassocthai.org/journal>

Adenosarcoma, a variant of mixed mesodermal tumor of the uterus, was initially reported by Clement and Scully in 1974⁽¹⁾. It usually arises in the endometrium and is characterized by a biphasic tumor, composed of benign epithelial elements and a sarcomatous stroma. In addition to the endometrium, a few extrauterine cases have been reported in the cervix, ovary, fallopian tube, urinary bladder, or pelvic peritoneum^(2,12). The authors report another case of primary peritoneal adenosarcoma with stromal overgrowth and fetal-type cartilage and make a review of the related literature.

Case Report

A previously healthy 48 year-old Thai multiparous woman was referred to Buddhachinaraj Hospital because of right lower quadrant pain in January 2003. On physical and pelvic examination, the

Correspondence to :Kanngurn S, Department of Pathology, Faculty of Medicine, Prince of Songkla University, Songkla 90110

patient was found to have a large abdominal mass. Ultrasound study showed a large complex, inhomogeneous mass, 25 cm in maximal diameter with cystic and solid components. The presumptive diagnosis was ovarian carcinoma. She underwent laparotomy subsequently.

Pathologic findings

Multiple polypoid fragile masses were received, measuring 26 x 26 x 10 cm in aggregate diameter. They were soft, semitranslucent and yellow brown color (Fig. 1). Necrosis and hemorrhage were observed. Multiple small firm nodules of hyaline cartilage were seen macroscopically. Histologic evaluation revealed biphasic a tumor which was composed of irregular cystically-dilated glands with benign columnar epithelium. The cellular stroma contained bland-looking spindle cells with feature of periglandular cuffing (Fig. 2, 3). Mitosis was 2 per 10 HPFs. Within the stroma were foci of fetal-type cartilage (Fig. 4). The stromal overgrowth displayed

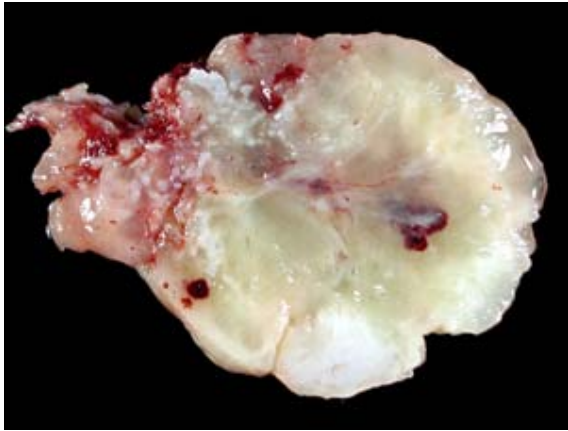
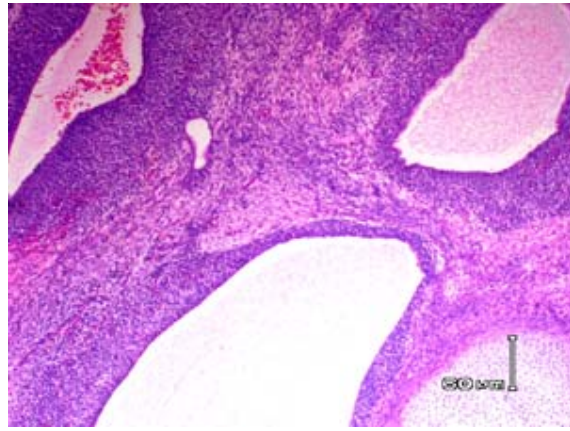
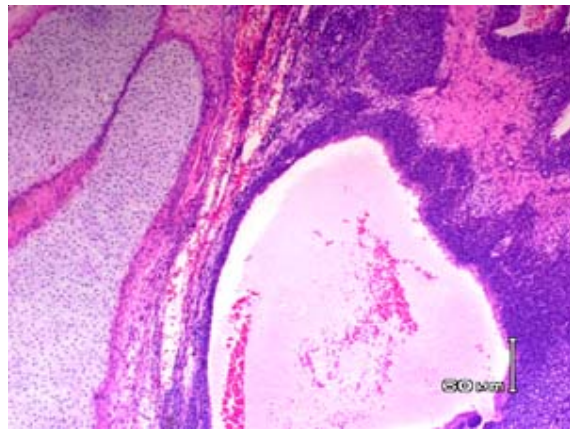


Fig. 1 Gross finding of one polypoid fragment of tumor. Note the cartilage nodules

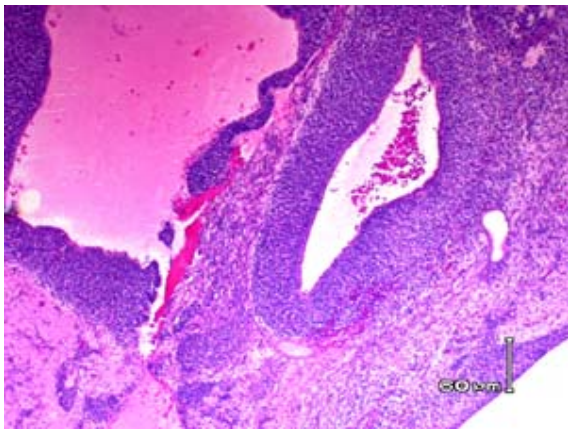


A

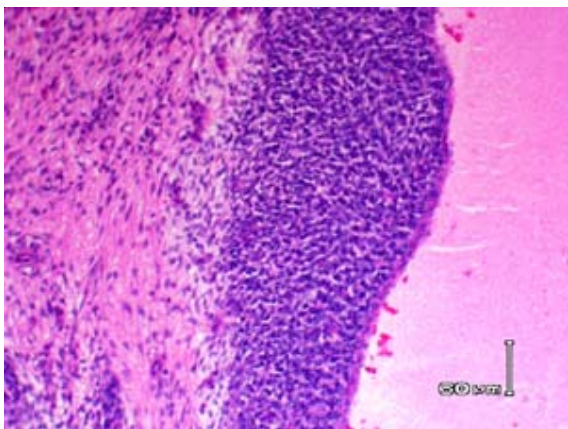


B

Fig. 2A, B Peritoneal adenosarcoma. The tumor shows biphasic appearance, composed of benign epithelial element and sarcomatous stromal component



A



B

Fig. 3 Note the benign-appearing glands surrounded by the stromal hypercellularity (periglandular cuffing), the characteristic feature of the adenosarcoma. A: Low power B: High power

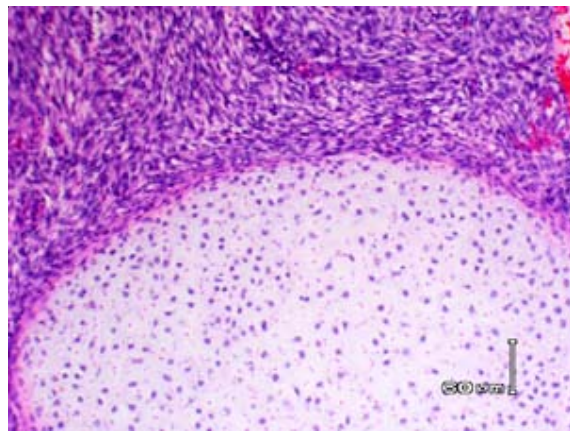
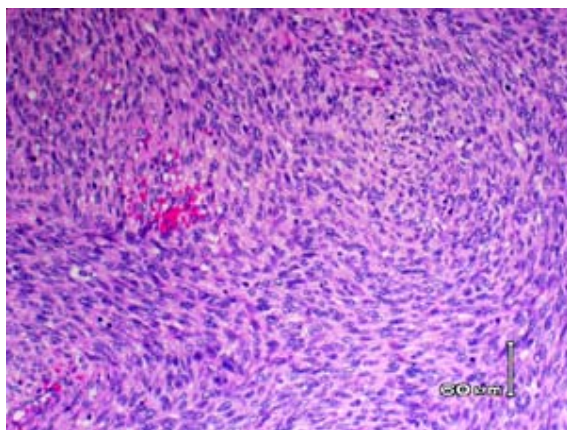
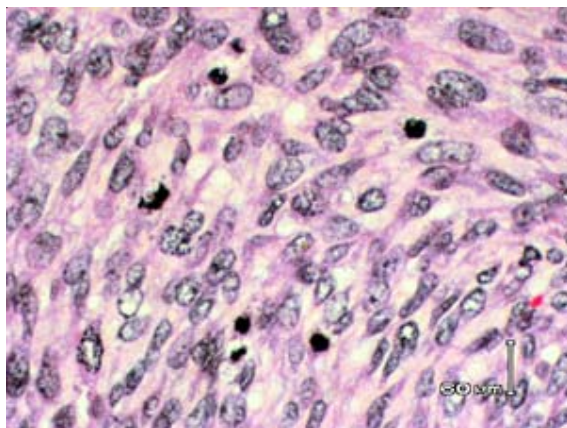


Fig. 4 Foci of cartilage, indicating heterologous differentiation in the stromal component

by > 25% of the tumor had pure sarcoma without epithelial component was also seen (Fig. 5). The immunohistochemical study reveals reciprocal reactive in both components of the tumor. The glandular structures stained positively for AE1/AE3 cytokeratin as usual as other epithelial tumors. The spindle cells showed reactivity for vimentin but were nonreactive for the S-100 protein (neural marker), desmin and muscle-specific actin (muscle markers). The cartilaginous nodules stained positively for the S-100 protein only as always see in other cartilaginous lesions. The immunohistochemical study to identify estrogen and progesterone receptors, p53 protein, and HER-2/neu protein was negative for both components. The excised uterus and both adnexa disclosed no evident of tumor. Primary peritoneal adenosarcoma with stromal overgrowth and fetal-type cartilage was diagnosed.



A



B

Fig. 5 Adenosarcoma with stromal overgrowth. Several mitoses are present. A: Low power, B: High power

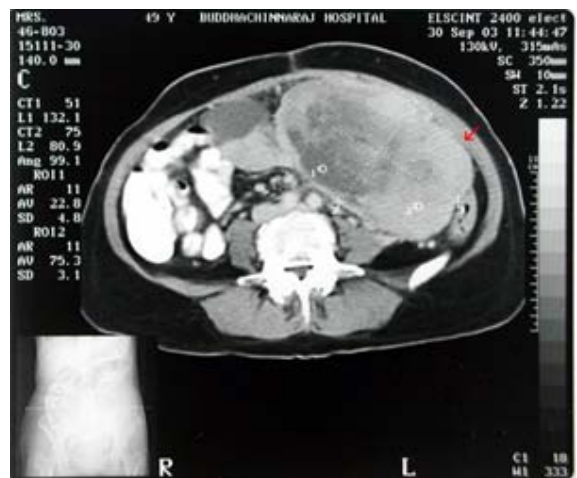

Fig. 6 Contrasted CT scan of recurrent intraperitoneal tumor, showing heterogeneous enhancing mass. The arrow indicates the thick peritoneum

Clinical follow-up

The patient was started on adjuvant chemotherapy, protocol BEP (Bleomycin, Etoposide, and Cisplatinum) for 7 cycles. The CT follow-up after 2 cycles revealed no evidence of recurrent or metastatic tumor. Unfortunately, the patient had a recurrent tumor after the fourth cycle chemotherapy in September 2003. The CT scan revealed a large well-defined multiloculated inhomogeneous intraperitoneal mass, measuring 13.5x7.8x13 cm (Fig. 6). The liver and spleen showed no apparent metastasis. The patient was referred to Rajavithi Hospital for additional radiation therapy but the medical oncologist there suggested the patient receive the same chemotherapy protocol with no additional radiation therapy. The patient was transferred back and has been lost to follow up since then.

Discussion

The mullerian adenosarcoma (AS) are infrequent uterine neoplasms, representing 8% of uterine sarcoma⁽¹³⁾. It is comprised of benign glandular and malignant stromal components. The latter may either be homologous (fibroblasts and smooth muscle) or heterologous (cartilage, striated muscle, bone, etc.). Most of AS occurs in the endometrium of postmenopausal women, the median age being 58 years⁽¹⁴⁾. The risk factor is unknown. Unlike uterine carcinoma, there is no association with obesity or hypertension. Interestingly, Carvalho et al reported mullerian adenosarcoma of the uterus after tamoxifen treatment for breast carcinoma in a 52-year-old patient but the

exact mechanism of development of the tumor is unclear⁽¹⁵⁾.

Extrauterine adenosarcoma was first reported in 1978⁽⁷⁾. To the authors' knowledge, no more than 20 similar cases of extragenital mullerian adenosarcoma have been published in the English literature (Table 1)⁽²⁻¹²⁾. The average age of the patient was 48.3 years which seemed to be 10 years younger than those with uterine adenosarcoma⁽⁷⁾.

The origin of extragenital adenosarcoma is not well documented. It has been hypothesized that these tumors arise either from endometriosis or from pluripotent mesothelial and mesenchymal cells of the pelvic cavity^(2,5,7). The histogenesis of AS does not correlate with P53 tumor suppressor gene mutation and HER-2/neu overexpression⁽¹⁶⁾. The cytogenetic study of adenosarcoma has been documented recently. The tumor reveals abnormal karyotype in chromosome 2 and 8 but the exact conclusion has been limited due to the number of cases⁽¹⁷⁾.

Microscopically, the extrauterine adenosarcoma has the same histologic feature as its uterine counterpart. The benign epithelium component usually is endometrial glands occasionally showing focal atypia and metaplastic changes. The sarcomatous tissue around glands may exhibit heterologous differentiation such as skeletal muscle or cartilage or may show sex cord-like patterns of growth. The differential diagnoses include endometriosis, adenofibroma and malignant mixed mullerian tumor. In some reported cases which have low stromal cellularity, they may be mislead as benign⁽²⁾. Clement and Scully proposed that the diagnosis of adenosarcoma can be made when one or more of the following criteria

are present: 1) a stromal mitotic count of ≥ 2 mitotic figures per 10 high power fields; 2) marked stromal cellularity; 3) more than a mild degree of nuclear atypia of the stromal cells. The characteristic periglandular stromal cuffing of adenosarcoma, as the present case illustrates, was a more reliable criterion than other parameters to distinguish from other mixed mullerian tumors. The stromal hypercellularity, frequent mitosis, and presence of heterologous element are unusual in endometriosis⁽⁶⁾.

The management of the extrauterine adenosarcoma is a debulking procedure to remove all visible tumor nodules^(4,15,18). The uterus and ovaries can be preserved for fertility in young reproductive women⁽¹⁹⁾. The role of postoperative pelvic radiation and chemotherapy is unclear. Adjuvant radiation therapy is often recommended for local tumor control in the pelvis but does not influence long-term survival because these tumors are generally not radiosensitive^(1,9). Most chemotherapy regimens were developed for treatment of mullerian adenosarcoma. Doxorubicin is widely used alone or in combination with cyclophosphamide, ifosfamide or vincristine. Unfortunately, the AS, as well as other gynecologic sarcomas, has an inconsistent response to doxorubicin-based chemotherapy in contrast to soft tissue sarcoma⁽⁵⁾. The use of cisplatin-based combination therapy (cyclophosphamide, doxorubicin, and cisplatin) showed partial response in a short duration but also had no effect on the overall survival^(5,18). On the other hand, some authors quote ifosfamide and mesna, with or without cisplatin have more utility⁽⁶⁾.

Although adenosarcoma is less aggressive than malignant mixed mullerian tumor, 25% of cases

Table 1. Cases of Peritoneal Adenosarcoma Reported in the Literature

Authors	Age	Diagnosis	Therapy	Follow-up
Russell et al ⁽⁸⁾	29	Adenosarcoma, homologous	Sx, RT	18 months remission
Kerner et al ⁽¹⁰⁾	32	Adenosarcoma, homologous	Sx	22 months remission
Clement et al ⁽⁷⁾	45	Adenosarcoma, homologous	Sx, RT	Died 9 months, sepsis, pelvic recurrence, visceral metastases
	73	Adenosarcoma, homologous	Sx	Died 2 months, CVA
	58	Adenosarcoma, homologous	Sx	15 months, local recurrence-RT; 45 months, lung metastases
Bard et al ⁽⁸⁾	46	Adenosarcoma, homologous	Partial resection, RT	Died 11 weeks, sepsis, lung and pelvic metastases
De Jonge et al ⁽⁵⁾	16	Adenosarcoma, heterologous	Sx, Chemo	57 months remission
Visvalingam S et al ⁽²⁾	50	Adenosarcoma, homologous	Sx, Hormonal therapy	Pelvic recurrence 1 year; died 16 months
Present case	48	Adenosarcoma, heterologous	Sx, chemo	Local recurrence 8 months

Note: Sx, Surgery; chemo, chemotherapy; RT, radiotherapy

have a pure sarcoma recurrence in the pelvis and 5% of patients have distant metastases. In a large series of Clement and Scully, the recurrence of mullerian adenosarcoma was diagnosed up to 9.5 years after primary treatment so long-term follow up is warranted⁽¹⁾. The presence of heterologous element may be a more clinically aggressive tumor^(6,9). The adenosarcoma with sarcomatous overgrowth has a higher recurrence rate and a poor prognosis similar to that of carcinosarcoma^(13,20). In addition, the extra-uterine counterparts may also have poorer outcome because they often are diagnosed in a more advanced stage and they are not protected by muscular thickness of the uterus⁽⁷⁾. Moreover, peritoneal adenosarcoma usually has had incomplete surgical debulking since the initial operation. The residual tumor is seen either macroscopically or microscopically. Surgery plays a role in removing the recurrent tumor and relieving symptoms. Additional therapy with radiation and chemotherapy provides a short response time of 6 months. The hormonal therapy has been raised for use in advanced disease⁽²¹⁾. To the authors' knowledge, many female cancers have variable response to hormonal treatment. It is most effective where the tumor cells have receptors for the hormone estrogen and progesterone^(21,22). Megace (progesterin megestrol acetate) is accepted as the primary hormone treatment used for the treatment of advanced or recurrent uterine cancer. To date, only one case has demonstrated the usefulness of the drug for the treatment of disseminated adenosarcoma. The disease free interval is 10 months after operation but the long term clinical course should be followed⁽²²⁾. Because of the small number of tumors, the prognostic factors indicating recurrence or survival of the patients are still debated.

Conclusion

The present case report demonstrates the rare extragenital adenosarcoma occurring in pelvic peritoneum. The two main points of concern are the diagnosis and the treatment course. The stromal overgrowth and presence of heterologous element should be reported because they reflect the greater aggressiveness of the tumor, thus, the patient may need more intensive treatment and long term follow up. The treatment protocols as well as chemotherapy responses are variable among the reported cases. More collective data is needed to recruit and establish the therapeutic protocols.

Acknowledgements

The authors wish to thank Assistant Professor Tuenjai Chuangsuwanich (Department of Pathology, Siriraj Hospital, Mahidol University) for reviewing the histopathology slides and for her helpful comments and Dr. Nitaya Thongsibkao (Department of Radiology, Buddhachinaraj Hospital) for providing the photocopy of CT scan.

References

1. Clement PB, Scully RE. Mullerian adenosarcoma of the uterus: a clinicopathologic analysis of ten cases of a distinctive type of mullerian mixed tumor. *Cancer* 1974; 34: 1138-49.
2. Visvalingam S, Jaworski R, Blumenthal N, Chan F. Primary peritoneal mesodermal adenosarcoma: report of a case and review of the literature. *Gynecol Oncol* 2001; 81: 500-5.
3. Judson PL, Temple AM, Fowler WC Jr, Novotny DB, Funkhouser WK Jr. Vaginal adenosarcoma arising from endometriosis. *Gynecol Oncol* 2000; 76: 123-5.
4. Ramos P, Ruiz A, Carabias E, Pinero I, Garzon A, Alvarez I. Mullerian adenosarcoma of the cervix with heterologous elements: report of a case and review of the literature. *Gynecol Oncol* 2002; 84: 161-6.
5. de Jonge MJ, van Dam PA, Van Marck E, Prove A, van Oosterom AT. Primary extrauterine mullerian adenosarcoma of the peritoneum. *Gynecol Oncol* 1995; 57: 126-30.
6. Gollard R, Kosty M, Bordin G, Wax A, Lacey C. Two unusual presentations of mullerian adenosarcoma: case reports, literature review, and treatment considerations. *Gynecol Oncol* 1995; 59: 412-22.
7. Clement PB, Scully RE. Extrauterine mesodermal (mullerian) adenosarcoma: a clinicopathologic analysis of five cases. *Am J Clin Pathol* 1978; 69: 276-83.
8. Russell P, Slavutin L, Laverty CR, Cooper-Booth J. Extrauterine mesodermal (mullerian) adenosarcoma: a case report. *Pathology* 1970; 11: 557-60.
9. Bard E, Bard D, Vargas-Cortes F. Extra uterine mullerian adenosarcoma: a clinicopathologic report of a case with distant metastases and a review of the literature. *Gynecol Oncol* 1978; 6: 261-74.
10. Kerner H, Lichtig C, Beck D. Extra uterine adenosarcoma of the peritoneal mesothelium: a clinicopathologic and electron microscopic study. *Obstet Gynecol* 1989; 73: 510-3.
11. Nezhat CH, Malik S, Osias J, Nezhat F, Nezhat C. Laparoscopic management of 15 patients with infiltrating endometriosis of the bladder and a case of primary intravesical endometrioid adenosarcoma. *Fertil Steril* 2002; 78: 872-75.
12. Liu L, Davidson S, Singh M. Mullerian adenosarcoma of vaginal arising in persistent endometriosis: report

- of a case and review of the literature. *Gynecol Oncol* 2003; 90: 486-90.
13. Silverberg SG, Kurman RJ. Tumors of the uterine corpus and gestational trophoblastic disease, in Atlas of tumor pathology, third series, fascicle 3, Armed Forces Institute of Pathology, Washington DC 1992: 156-66.
 14. Clement PB, Scully RE. Mullerian adenosarcoma of the uterus: a clinicopathological analysis of 100 cases with a review of the literature. *Hum Pathol* 1990; 21: 363-81.
 15. Carvalho FM, Carvalho JP, Motta EV, Souen J. Mullerian adenosarcoma of the uterus with sarcomatous overgrowth following tamoxifen treatment for breast cancer. *Rev Hosp Clin Fac Med S Paulo* 2000; 55: 17-20.
 16. Swisher EM, Gown AM, Skelly M, Ek M, Tamimi HK, Cain JM, et al. The overexpression of epidermal growth factor receptor, HER-2/neu, p53, and Ki-67 antigen in uterine malignant mixed mesodermal tumors and adenosarcoma. *Gynecol Oncol* 1996; 60: 81-8.
 17. Chen Z, Hong B, Drozd-Borysiuk E, Coffin C, Albritton K. Molecular cytogenetic characterization of a case of mullerian adenosarcoma. *Cancer Genet Cytogenet* 2004; 148: 129-32.
 18. Del Carmen MG, Lovett D, Goodman A. A case report of mullerian adenosarcoma of the uterus treated with liposomal doxorubicin. *Gynecol Oncol* 2003; 88: 456-8.
 19. Michener C, Simon NL. Ovarian conservation in a woman of reproductive age with mullerian adenosarcoma. *Gynecol Oncol* 2001; 83: 89-94.
 20. Krivak TC, Seidman JD, McBroom JW, MacKoul PJ, Aye LM, Rose GS. Uterine adenosarcoma with sarcomatous overgrowth versus uterine carcinosarcoma: comparison of treatment and survival. *Gynecol Oncol* 2001; 83: 89-94.
 21. Amant F, Gabriel C, Moerman P, Vergote I. Immunohistochemical determination of hormone receptors in uterine adenosarcomas. *Gynecol Oncol* 2003; 88: 463-4.
 22. Hines BJ, Porges RF, Mittal K, Muggia FM, Curtin JP. Use of medroxyprogesterone acetate in the treatment of mullerian adenosarcoma: a case report. *Gynecol Oncol* 2002; 85: 192-5.

เนื้องอกปฐมภูมิชนิดอะดิโนซาร์โคมาของเยื่อบุช่องเชิงกรานที่มีเนื้อเยื่อค้ำจุนเจริญมากเกินไป และเนื้อเยื่อกระดูกอ่อน: รายงานผู้ป่วย 1 รายและทบทวนรายงานในอดีต

สมรมาศ กันเงิน, จุลินทร สำราญ, ชชาติชาย อาจองค์, วิสุทธิ์ ล้ำเลิศธน, สุชาติ พรเจริญพงศ์

รายงานเนื้องอกปฐมภูมิชนิดอะดิโนซาร์โคมาของเยื่อบุช่องเชิงกรานที่มีเนื้อเยื่อค้ำจุนเจริญมากเกินไป และเนื้อเยื่อกระดูกอ่อนในผู้ป่วยหญิงอายุ 48 ปี ผลการตรวจพบว่าเนื้องอกเจริญอยู่ในเยื่อบุช่องเชิงกราน โดยที่มดลูก รังไข่ และท่อนำไข่ปกติ เนื้องอกชนิดอะดิโนซาร์โคมามีรายงานพบประปรายที่ปากมดลูก รังไข่ ท่อนำไข่ กระเพาะปัสสาวะ และเยื่อบุช่องเชิงกราน รายงานฉบับนี้เป็นรายงานผู้ป่วยรายที่ 9 ของเนื้องอกชนิดนี้ ที่พบในเยื่อบุช่องเชิงกรานที่มีการรายงานไว้ในงานวิจัยที่ตีพิมพ์เป็นภาษาอังกฤษ และเป็นรายงานผู้ป่วยรายแรกในประเทศไทย